

Contents lists available at ScienceDirect

## Radiotherapy and Oncology

journal homepage: [www.thegreenjournal.com](http://www.thegreenjournal.com)

## Original Article

## ESTRO-EANO guideline on target delineation and radiotherapy for IDH-mutant WHO CNS grade 2 and 3 diffuse glioma

Brigitta G. Baumert<sup>a,\*</sup>, Jaap P. M. Jaspers<sup>b</sup>, Vera C. Keil<sup>c</sup>, Norbert Galldiks<sup>d,p,q</sup>, Ewa Izycka-Swieszewska<sup>e</sup>, Beate Timmermann<sup>f,t,u</sup>, Anca L. Grosu<sup>g</sup>, Giuseppe Minniti<sup>h</sup>, Umberto Ricardi<sup>i</sup>, Frédéric Dhermain<sup>j</sup>, Damien C. Weber<sup>k</sup>, Martin van den Bent<sup>l</sup>, Roberta Rudà<sup>m</sup>, Maximilian Niyazi<sup>n,r</sup>, Sara Erridge<sup>o,s</sup>

<sup>a</sup> Institute of Radiation-Oncology, Cantonal Hospital Graubünden, Chur, Switzerland<sup>b</sup> Department of Radiation Oncology, Radboud University Medical Center, Nijmegen, Netherlands<sup>c</sup> Department of Radiology and Nuclear Medicine, Amsterdam University Medical Center, Amsterdam, Netherlands<sup>d</sup> Department of Neurology, Faculty of Medicine and University Hospital Cologne, University of Cologne, Cologne, Germany<sup>e</sup> Department of Pathology and Neuropathology, Medical University of Gdansk, Gdansk, Poland<sup>f</sup> West German Proton Therapy Centre Essen (WPE), University Hospital Essen, Essen, Germany<sup>g</sup> Department of Radiation Oncology, University Medical Center, Medical Faculty, University of Freiburg, Freiburg, Germany<sup>h</sup> Radiation Oncology Unit, Department of Radiological Sciences, Sapienza University of Rome, Rome, Italy<sup>i</sup> Department of Oncology, University of Turin, Turin, Italy<sup>j</sup> Radiation Oncology Department, Gustave Roussy University Hospital, Villejuif, France<sup>k</sup> Center for Proton Therapy, Paul Scherrer Institute, Villigen PSI, Villigen, Switzerland<sup>l</sup> The Brain Tumor Center at Erasmus MC Cancer Institute, University Medical Center Rotterdam, Rotterdam, Netherlands<sup>m</sup> Division of Neuro-Oncology, Department of Neuroscience, University of Turin, Turin, Italy<sup>n</sup> Center for Neuro-Oncology, Comprehensive Cancer Center Tübingen-Stuttgart, University Hospital Tübingen, Tübingen, Germany<sup>o</sup> Edinburgh Cancer Centre, Western General Hospital, Edinburgh, UK<sup>p</sup> Institute of Neuroscience and Medicine (IMN-3), Research Center Juelich, Juelich, Germany<sup>q</sup> Center for Integrated Oncology Aachen Bonn Cologne Duesseldorf (CIO ABCD), Germany<sup>r</sup> Department of Radiation Oncology, University Hospital Tübingen, Tübingen, Germany<sup>s</sup> Institute of Genetics and Cancer, University of Edinburgh, Edinburgh, UK<sup>t</sup> Department of Particle Therapy, University Hospital Essen, Essen, Germany<sup>u</sup> West German Cancer Centre (WTZ), German Cancer Consortium (DKTK), Essen, Germany

## ARTICLE INFO

## Keywords:

IDH-mutant diffuse glioma  
Low grade glioma  
Anaplastic glioma  
Target volume  
Delineation  
Radiotherapy

## ABSTRACT

**Purpose:** This guideline will discuss radiotherapeutic management of IDH-mutant grade 2 and grade 3 diffuse glioma, using the latest 2021 WHO (5th) classification of brain tumours focusing on: imaging modalities, tumour volume delineation, irradiation dose and fractionation.

**Methods:** The ESTRO Guidelines Committee, CNS subgroup, nominated 15 European experts who identified questions for this guideline. Four working groups were established addressing specific questions concerning imaging, target volume delineation, radiation techniques and fractionation. A literature search was performed, and available literature was discussed. A modified two-step Delphi process was used with majority voting resulted in a decision or highlighting areas of uncertainty.

**Results:** Key issues identified and discussed included imaging needed to define target definition, target delineation and the size of margins, and technical aspects of treatment including different planning techniques such as proton therapy.

**Conclusions:** The GTV should include any residual tumour volume after surgery, as well as the resection cavity. Enhancing lesions on T1 imaging should be included if they are indicative of residual tumour. In grade 2 tumours, T2/FLAIR abnormalities should be included in the GTV. In grade 3 tumours, T2/FLAIR abnormalities should also be included, except areas that are considered to be oedema which should be omitted from the GTV. A GTV to CTV expansion of 10 mm is recommended in grade 2 tumours and 15 mm in grade 3 tumours. A

\* Corresponding author.

E-mail address: [brigitta.baumert@gmail.com](mailto:brigitta.baumert@gmail.com) (B.G. Baumert).<https://doi.org/10.1016/j.radonc.2024.110594>

Received 10 October 2024; Accepted 12 October 2024

Available online 24 October 2024

0167-8140/© 2024 The Authors. Published by Elsevier B.V. This is an open access article under the CC BY-NC-ND license (<http://creativecommons.org/licenses/by-nc-nd/4.0/>).

treatment dose of 50.4 Gy in 28 fractions is recommended in grade 2 tumours and 59.4 Gy in 33 fractions in grade 3 tumours. Radiation techniques with IMRT are the preferred approach.

## Introduction

The 2016 and 2021 updates of the WHO Classification of Tumours of the Central Nervous System changed the diagnostic classification by the integration of molecular markers in the routine diagnostics of brain tumours [1,2]. IDH mutational status is now a key element in the classification of adult-type diffuse gliomas. IDH-mutant diffuse gliomas are then subdivided into those with 1p/19q codeletion (oligodendrogliomas) and without codeletion (astrocytomas). Tumours are then categorized into grades 2, 3 or 4 according to morphological and molecular features [3]. The change in classification introduces new challenges in translating results from past trials into present-day clinical care. In addition, new methods of radiotherapy dose-delivery, as well as the increased availability of advanced structural and functional imaging, warrant new consensus guidelines on radiotherapy for lower grade diffuse glioma. Therefore, the European Society for Radiotherapy and Oncology (ESTRO) together with the European Association of Neuro-Oncology (EANO) developed this guideline for radiotherapy of IDH-mutant, grade 2 and 3 diffuse gliomas in adults. High grade, WHO grade 4, gliomas (HGG) are addressed in a separate guideline [4].

## Methods

The ESTRO Guidelines Committee, CNS subgroup, nominated 16 European experts who identified areas of clinical uncertainty to be answered in this guideline. Four areas were addressed: 1). Imaging, 2). Radiotherapy (RT) volumes, 3). Radiotherapy techniques, and 4). Radiotherapy dose and fractionation.

Timing and sequencing of treatment were not included as this has been discussed extensively elsewhere [5].

For each topic, a literature search was performed including literature from 1990 to 2022. Both MeSH terms and text words were used with the

following search terms: (“Low grade glioma/radiotherapy” [MeSH] OR “higher grade glioma” OR “malignant glioma” OR high-grade glioma) AND ((delineation) OR (target volume) OR (CTV) OR (PTV) OR (margin) OR (recurrence pattern) OR (contouring) OR (organs at risk) OR (radiation technique /brachytherapy/protons). For the imaging section of this guideline, a separate search was performed including the terms “MRI” and “magnetic resonance imaging” and “CT”. Additionally, national guidelines from the Netherlands, USA and the UK, and trial protocols from the EORTC, were consulted. It was agreed upon that only literature-based 3D-conformal or more sophisticated radiotherapy should be included. The final literature review was conducted in July 2023.

The findings from the literature search were discussed in regular online meetings and are summarised in Tables 1 to 4. Decisions were made by a majority vote with at least a of 51 % agreement in case of open questions. Open questions were identified, and recommendations made according to a modified Delphi process – 13 out of 15 experts took part in two predefined rounds in which 65 % agreement was defined as ‘consensus’ and 80 % as ‘strong consensus’. Table 5.

Additional experts from the EANO (MvdB, RR) participated in reviewing and drafting the manuscript.

## Results

### Imaging

Currently, 3 Tesla (3 T) MRI is the desired clinical standard, while 1.5 T is also completely acceptable despite a lower signal-to-noise ratio [6] (Delphi: strong consensus [92.9 %]). There are also, promising studies suggesting that ultra-high field (starting at 7 T) may provide superior images for dose planning [7].

There is a widely accepted standardized imaging protocol for

**Table 1**

Trials investigating adjuvant chemotherapy in grade 2 and 3 diffuse gliomas.

Trial name	Inclusion	Astro		Oligo		“Oligo astro”	Randomisation	Radiotherapy	Conclusions
		2	3	2	3	2	3		
RTOG9802 [83]	1998–2002	x		x		x	PCV vs observation	30*1.8 Gy	PCV improved OS (13.3 vs 7.8y).
RTOG9402 [76]	1994–2002				x	x	PCV vs observation	33*1.8 Gy	PCV did not improve OS (4.6 vs 4.7y). However, significant OS benefit in 1p/19q codeleted tumours (14.7 vs 7.3y).
EORTC 26,951 [77]	1995–2002				x	x	PCV vs observation	33*1.8 Gy	PCV improved OS (3.5 vs 2.6 y).
RTOG0424 [84]	2005–2009	x		x		x	TMZ concurrent or adjuvant vs historical controls	30*1.8 Gy	Inclusion based on >3 Pignatti risk factors. OS 8.2 years was an improvement over historical controls.
CATNON [75]	2007–2015		x				TMZ concurrent vs TMZ adjuvant vs TMZ concurrent and adjuvant vs observation (2x2 design)	33*1.8 Gy	TMZ adjuvant improved OS (6.9 vs 3.9y). TMZ concurrent did not improve OS (5.6 vs 5.0y).
NOA04 [78]	1999–2005		x		x	(x)	Observation vs PCV vs TMZ (2–1–1 design)	No data	No OS benefit for chemotherapy (8.0 vs 6.5y)
RTOG9813 [85]	2002–2007		x				PCV vs TMZ	33*1.8 Gy	No difference in OS (3.9y vs 3.8y). TMZ was better tolerated.

primary brain tumours [8], but this is focused on reaching the correct diagnosis and is not optimized for postsurgical treatment planning. The imaging protocol for RT planning must optimally define tumour borders without geometric image distortions. Three-dimensional (3D) sequences applying gap-free isotropic voxels of 1 mm or less are advised to guarantee a spatial resolution of images with minimal geometric distortions [9]. Geometric distortions can compromise the accuracy of delineation and planning, and should be reduced. This can be accomplished using post-processing tools, which often occurs automatically during reconstruction. Infratentorial lesions show improved rigid CT co-registration if the head position on CT and MRI matches but mask immobilisation for RT planning MRI is not the clinical standard [10].

For RT planning, it is recommended to use a combination of a 3D T2-weighted fluid-attenuated inversion recovery sequence (FLAIR) and a 3D T1-weighted sequence with and without contrast. 3D T1-weighted sequences can differ in image contrast of grey and white matter [11]. Greater structure contrast can be achieved by use of intravenous gadolinium-based contrast agent administration, which identifies tumour regions showing blood–brain barrier disruption which can indicate areas of tumour transformation to a higher-grade lesion. Technically it is possible to delineate grade 2 and 3 diffuse glioma only on T2-weighted images without contrast-enhanced MRI sequences. The early post-operative MRI scan (<48–72 h after surgery) can have surgical cellular debris and infarctions which can disguise or mimic RT-relevant tumour, and perifocal tumour oedema may not have resolved or may even extend. So, for lower grade diffuse glioma, where growth is slow, there is the time to enable these changes to resolve (e.g., repeat scan 3–4 months after surgery) [12]. Consequently, a new MRI scan is recommended when RT is being planned to enable more precise target delineation.

Following radiotherapy, most guidelines recommend an initial interval between follow-up MRIs of 3 to 6 months, that can be extended to 9 to 12 months in stable patients. Additionally, a baseline MRI scan on completion of radiotherapy is recommended [13]. Of note, a substantial proportion of irradiated lower grade gliomas shows signs of pseudo-progression or other treatment related changes [14–17], which can trigger unnecessary interventions such as surgery as well as patient stress. Therefore, clinically stable patients should preferably receive follow-up with the lowest frequency acknowledged acceptable in their recommended interval range (Delphi: consensus [84.6 %]) with a full brain tumour imaging protocol [8].

A CT scan remains a crucial step in RT planning for two reasons; firstly, the images provide the geometric gold standard that the more distorted MRI images can be co-registered to and secondly it provides the electron density information necessary for dose planning. No specific technical prerequisites apply towards lower grade diffuse gliomas, and standard protocols can be found elsewhere [18]. However, at craniotomy metal clips are often used for skull plate fixation, and the use of

**Table 3**

Overview of target volume definitions from published trials (adapted from [41]).

Trial name	Procedure	Target	ICRU definition
<i>Grade 2</i>			
EORTC 22,844 [44]	CT enhancing lesion + 20 mm	Target volume	ICRU29
EORTC 22,845 [38]	CT edema + 10 mm	Target volume	ICRU29
RTOG 9802 [83]	MRI T2 abnormalities + 20 mm	Field edge	ICRU29
Intergroup [73]	MRI T2 abnormalities + 20 mm	Target volume	ICRU29
EORTC 22,033 [47]	Lesion on CT or MRI + 20 mm	CTV	ICRU50
RTOG 0424 [84]	MRI T1 enhancement and T2 abnormalities + 15 mm	CTV	ICRU50
<i>Grade 3</i>			
RTOG 9402 [76]	MRI T2 abnormalities + 20 mm to 50.4 Gy	Target volume	ICRU29
EORTC 26,951 [77]	MRI T1 enhancement + 10 mm to 59.4 Gy	PTV	ICRU50
EORTC 26,053 (CATNON) [75]	CT edema OR MRI T2 abnormalities + 25 mm to 45 Gy	CTV	ICRU50
NOA04 [78]	CT enhancing lesion OR MRI T1 enhancement to 59.4 Gy	CTV	ICRU50
Alliance N0577 [86]	MRI T2 abnormalities + 15 – 20 mm	CTV	ICRU50
	MRI abnormalities + 20 mm	CTV	ICRU50
	MRI T2 abnormalities + 10 mm to 50.4 Gy*	CTV	ICRU50
	MRI T2 abnormalities + 0 mm to 59.4 Gy*		

metal-artifact suppression acquisition techniques is recommended to optimize the accuracy of Hounsfield (HU) calculations.

Radiolabelled amino acids are of particular interest for glioma imaging using PET as their increased uptake in neoplastic tissue but low uptake in the normal brain parenchyma results in an improved tumour-to-brain contrast [18]. Most frequently used amino acid tracers are [<sup>11</sup>C-methyl]-L-methionine (MET), O-(2-[<sup>18</sup>F]-fluoroethyl)-L-tyrosine (FET), and 3,4-dihydroxy-6-[<sup>18</sup>F]-fluoro-L-phenylalanine (FDOPA). Radiolabelled amino acids exhibit a sensitivity of more than 90 % for glioma, however only around 70 % of lower grade diffuse gliomas

**Table 2**

Trials investigating radiotherapy dose and timing in grade 2 and 3 diffuse glioma.

Trial name	Inclusion	Astro		Oligo		“Oligo astro”	Randomisation	Radiotherapy	Conclusions	
		2	3	2	3	2	3			
<i>Early vs late</i>										
EORTC 22,845 [38]	1986–1997	x		x		x		RT vs observation	28*1.8 Gy	No OS benefit (7.4 vs 7.2y) but PFS benefit (5.3 vs 3.4y) for early RT
Alliance N0577 (CODEL) [86]	2009–2011				x			RT vs RT + TMZ vs TMZ	33*1.8 Gy	PFS worse in TMZ only arm (5y PFS 56 % vs 33 %). Study design changed to RT + PCV vs RT + TMZ
EORTC 22,033 [47]	2005–2010	x						RT vs TMZ	28*1.8 Gy	No difference in PFS (3.8 vs 3.3y)
<i>Dose escalation</i>										
EORTC22844 [44]	1985–1991	x		x		x		RT vs dose-escalated RT	25*1.8 Gy vs 33*1.8 Gy	No OS benefit (5y OS 58 % vs 59 %) or PFS benefit (5y PFS 47 % vs 50 %) for high dose RT
Intergroup [73]	1986–1994	x		x		x		RT vs dose-escalated RT	28*1.8 Gy vs 36*1.8 Gy	No OS benefit (15y OS 22 % vs 25 %) or PFS benefit (15y PFS 15 % vs 10 %) for high dose RT

**Table 4**

Overview of published series in grade 2 and 3 diffuse glioma with pattern of failure data (adapted from [41]).

	Margin	Number of recurrences	In field	Field edge	Out of field
<i>Grade 2</i>					
Pu, 1994 [36]	10 – 30 mm to target volume	11	100 %	0 %	0 %
Rudoler, 1998 [37]	20 mm to target volume	16	100 %	0 %	0 %
van den Bent, 2005 [38]	20 mm to target volume	94	90 %	5 %	4 %
Shaw, 2002 [39]	20 mm to target volume	65	92 %	3 %	5 %
Kamran, 2019 [40]	7–15 mm to CTV	41	76 %	12 %	12 %
Jaspers, 2021 [41]	10 – 15 mm to CTV	39	92 %	0 %	8 %
<i>Grade 3</i>					
Im, 2018 [43]	15–20 mm to CTV	31	61 %	19 %	16 %
Back, 2020 [42]	10 mm to CTV	68	51 %	9 %	22 %

\* Proton therapy series, WHO grade 1 and 2 glioma.

\*\* The data shown pertains to isolated local, marginal, and distant relapses. In the remaining 12 (18%) patients recurrence was classified as a combination of local, marginal and distant failure.

exhibit increased uptake [19–22]. Thus, 20–30 % of these gliomas are amino acid PET negative (i.e., no increased uptake compared to the reference region). Of note, a subgroup of patients with lesions without amino acid uptake on PET and MRI findings suspicious for low grade gliomas (i.e., hyperintense T2/FLAIR signal without contrast enhancement) may even show photopenic defects (i.e., uptake visually lower than the reference region) and harbour high grade gliomas [23,24]. Conventional MRI is limited in its ability to differentiate between oedema, ischaemia, inflammation, and non-enhancing gliomas. For PET, several studies have correlated histology obtained from tissue specimens with amino acid uptake and provide evidence that amino acid PET detects the most malignant tumour parts more reliably than conventional MRI [25–30]. Therefore, amino acid PET appears highly valuable for

target delineation. A more recent publication by the Response Assessment in Neuro-Oncology Working Group for PET (PET/RANO), summarizes the data and concluded that in glioma patients (including non-enhancing gliomas) amino acid PET may improve the delineation of radiotherapy target volumes beyond conventional MRI and identify additional tumour parts that should be targeted by radiotherapy [31]. According to current guidelines for glioma imaging using amino acid PET, the threshold for FET uptake for the delineation of tumour extent is defined as a mean tumour-to-brain ratio of 1.6 [32].

### Radiotherapy volumes

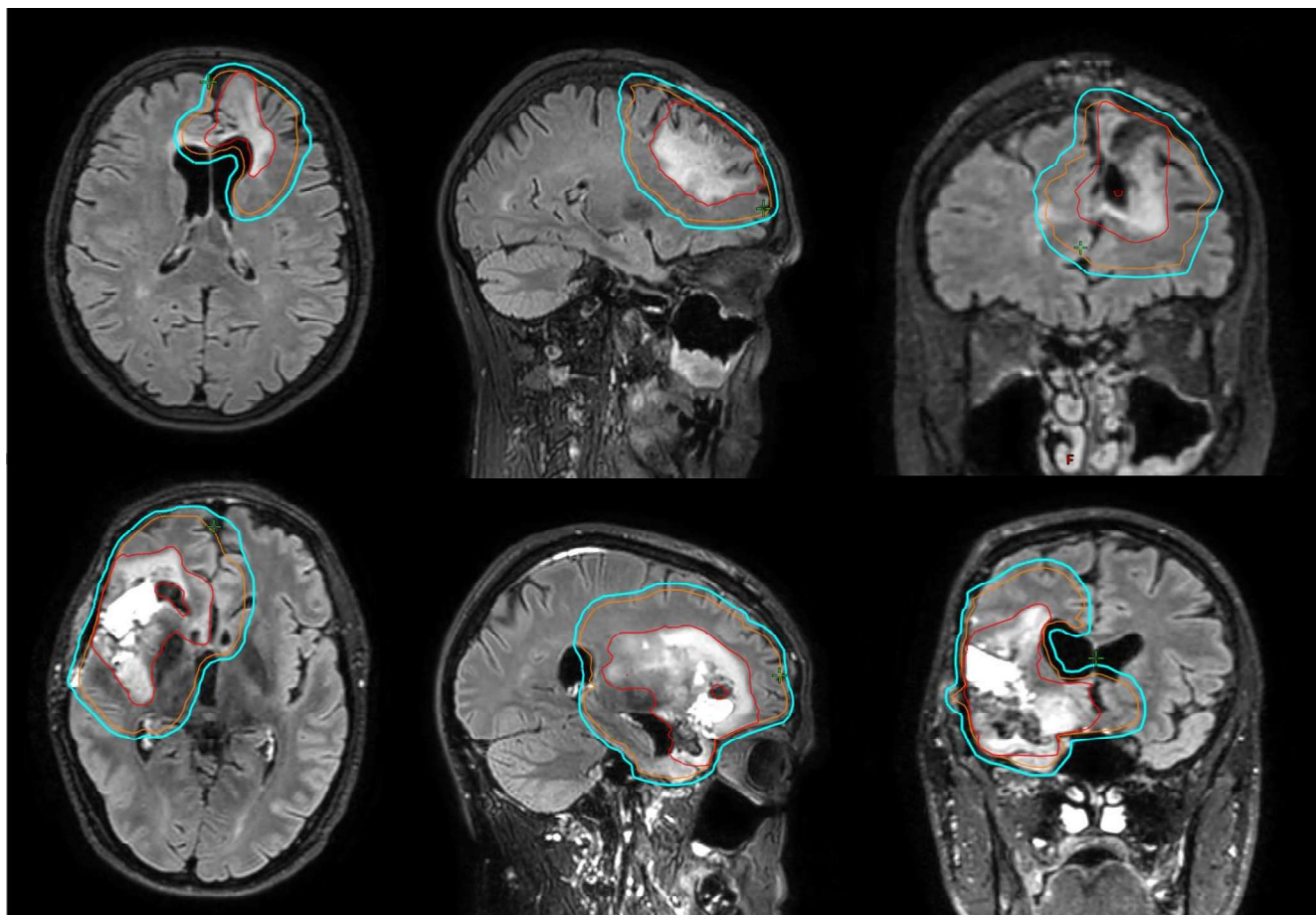
Almost all patients with grade 2 and 3 diffuse glioma will at some time point undergo disease progression, typically in close proximity to the resection cavity following surgery [33–35]. More than 80 % of patients with grade 2 tumours exhibit treatment failure within the original RT fields [36–41]. Data on grade 3 tumours is limited, but the available evidence suggests higher rates of marginal and out-field failure [42,43]. There has been gradual reduction of field size over the last three decades prompted by; a) the pattern of mainly in-field recurrences, b) ongoing improvements in imaging, RT planning and dose delivery, and c) the longer overall survival increases concerns about late side effects of radiotherapy resulting from large treatment volumes. For grade 2 glioma, the landmark trials of the 1990's and 2000's typically adopted margin concepts that would amount to a CTV margin of 15 to 20 mm [38,39,44,45] around the resection cavity and any residual lesion on imaging. Later trials recommended a CTV margin to 15 mm in all patients [46,47], and current ongoing trials prescribe a CTV margin of 10 mm (NRG BN005, Alliance N0557) or below (EORTC 1635)(Table 3). For grade 3 glioma the early studies used a similar or slightly larger margins, with an additional boost phase [48,49]. Currently most trials use a CTV margin of around 15 mm in a single-phase technique [50,51] Fig. 1. The PTV should take into account all possible geometric uncertainties of treatment delivery as well as measurements of each institute. For intracranial treatments, the use of a mask system and daily online image guidance with cone beam CT typically reduces both systematic and random errors to 1.5 mm or lower[52]. The working party agreed on the following target delineation guidance, considering published recurrence data and distances (Table 4).

**Table 5**

Results of modified Delphi.

Question	Topic	Answer	Level of agreement (%)
Imaging	MRI	3 Tesla MRI is desired clinical standard	92.9
	Pseudo-progression	clinically stable patients should receive follow-up with the lowest frequency acknowledged acceptable	84.6
RT volumes	GTV – general	GTV should include resection cavity and any residual tumour volume after surgery.	100
		Amino-acid PET and perfusion/diffusion advanced MRI can be good tools to improve the differentiation between oedema and tumour	92.9
	GTV – grade 2	T2/FLAIR abnormalities that are thought to represent tumour should be included in the GTV	100
	GTV – grade 3	T2/FLAIR abnormalities could either be tumour or oedema, but areas which are thought to represent oedema do not need to be included in the GTV	85.7
	CTV – grade 2	CTV should be created with an expansion of the GTV with a margin of 10 mm	90.9
	CTV – grade 3	CTV should be created with an expansion of the GTV 15 mm	91.7
	CTV – general	CTV margin should be edited to respect anatomical boundaries unless tumour invasion is explicitly suspected	100
RT techniques	Hippocampal sparing	If uni- or bilateral hippocampal sparing is used, the original constraint (D40% of bilateral hippocampus < 7.3 Gy) is recommended	91.7
	Planning	IMRT and VMAT are preferred approach due to the improved target conformity with associated better sparing of OARs	100
	Set-up control	Daily image guidance, including MV and KV cone beam CT and orthogonal X-ray imaging systems, is recommended	100
	Brachytherapy	application of interstitial brachytherapy adds to the treatment portfolio if used in experienced hands and selected cases	50
Dose, fractionation		50.4 Gy in 28 fractions is recommended	100
		54 Gy in 30 fractions as also used in several trials including the RTOG 9802, is also acceptable	83.3
		A lower dose level such as 45 Gy in 25 fractions, is advised against	100
		60 Gy in 30 fractions should not be exceeded in WHO grade 3 tumours	100





**Fig. 1.** Delineation of IDH-mutant lower grade glioma. GTV is in red, CTV in orange, PTV in blue. Top row: grade 2, CTV margin 10 mm, PTV margin 3 mm. Bottom row: grade 3, CTV margin 15 mm, PTV margin 3 mm. (For interpretation of the references to colour in this figure legend, the reader is referred to the web version of this article.)

#### GTV

- The GTV should include the resection cavity and any residual tumour volume after surgery (resection or biopsy). The same target delineation should be used for 1p/19q codeleted and non-codeleted glioma Enhancing lesions on T1 imaging should be included if they are indicative of residual tumour (Delphi: strong consensus [100 %]).
- In grade 2 tumours, T2/FLAIR abnormalities that are thought to represent tumour should be included in the GTV (Delphi: strong consensus [100 %]).
- In grade 3 tumours, T2/FLAIR abnormalities could either be tumour or oedema, but areas which are thought to represent oedema do not need to be included in the GTV (Delphi: strong consensus [85.7 %]).
- The delineation of the GTV can be informed by additional MRI and/or functional imaging. If available, amino acid PET and perfusion/diffusion MRI can be valuable tools to improve the differentiation between oedema and tumour (Delphi: strong consensus [92.9 %]).

#### CTV

- The CTV should be created with an expansion of the GTV with a margin of 10 mm for grade 2 tumours (Delphi: strong consensus [90.9 %]). and 15 mm for grade 3 tumours (Delphi: strong consensus [91.7 %]).
- The CTV margin should then be edited to respect anatomical boundaries, including the calvarium, tentorium, falx, and ventricles, and to exclude the optic nerves, chiasm, and pituitary gland (unless

tumour invasion is explicitly suspected) (Delphi: strong consensus [100 %]).

- The CTV should not be edited for areas where tumour spread is possible, such as hippocampus or corpus callosum.

#### PTV

- PTV is created using a margin of  $\leq 3$  mm depending on departmental set up policy.

#### Organs at risk

For organ-at-risk (OAR) delineation, the EPTN atlas contains definitions for the organs-at-risk used in CNS radiotherapy [53,54]. The atlas was developed for use in both photon and proton radiotherapy, its use is recommended in trials or multi-centre protocols. In photon radiotherapy the Intergroup atlas can be used as an alternative [55]. Preferably, all individual organs at risk should be contoured. Both atlases, as well as the ESTRO-EANO glioblastoma guideline, include OAR dose constraint guidance [4,56]. In addition to dose constraints, NTCP models can be used for both the purpose of patient selection and radiotherapy planning [57,58].

Although there is substantial interest in factors linked to late-onset neurocognitive decline in patients with grade 2 and 3 diffuse gliomas, demonstration of a direct relationship between RT dose parameters and cognitive outcome has so far been unsuccessful. The complex interplay between tumour location, baseline neurological functioning, along with the type and frequency of neurocognitive testing, make assessment of impact of RT dose for an individual patient challenging. The strongest

evidence exists for hippocampal avoidance, which has gained adoption in radiotherapy following the publication of RTOG 0933 [59]. If uni- or bilateral hippocampal sparing is used, the original constraint (D40% of bilateral hippocampus <7.3 Gy) is recommended (Delphi: strong consensus [91.7 %]). The mean dose to brain minus GTV (brain-GTV) can be considered as a planning objective and used to quickly compare plans with regards to dose in macroscopically uninvolved areas of the brain.

### Radiotherapy techniques and dose-prescription

In view of the long survival of patients with IDH-mutant diffuse gliomas, it is important to keep doses to organs at risk and healthy normal brain as low as possible. Though no randomized trials have compared available radiation techniques, IMRT and VMAT are the preferred approach over 3D conformal RT due to the improved target conformity with associated better sparing of OARs (Delphi: strong consensus [100 %]). Daily image guidance, including MV and KV cone beam CT and orthogonal X-ray imaging systems, is recommended to enable set up margins to be minimised (Delphi: strong consensus [100 %]).

The physical characteristics of the proton beam offers the potential to reduce the volume of brain receiving low doses of radiotherapy. Also, intensity modulation of proton beams is now available, providing superior dose distributions in complex shaped target volumes when compared to older proton therapy techniques. The use of proton beam therapy may be particularly relevant in patients at young age with tumours that convey a favourable prognosis, such as IDH-mutant grade 2 diffuse gliomas. However, some reports suggest an increased rate of contrast-enhancing changes or pseudo-progression following proton radiotherapy, particularly when RT was combined with chemotherapy [60,61]. In contrast, a German and a Swedish study did not find an increased risk of pseudo-progression after proton beam therapy when compared to photon therapy data [62,63]. In proton therapy, global health as a domain of QoL has remained stable and similar to the normative reference [64]. Currently, there are no published randomised trials in adults, but the NRGBN005, NOA GLioProPh, and UK APPROACH trials are currently recruiting patients with IDH-mutant gliomas randomising them between photon-based IMRT or protons, with change in cognition as the primary endpoint. The results of these and other trials in set up phase will help decision making in future, though the potential reduction in late morbidity with protons will require many years to be fully evaluated.

Brachytherapy involves the use of radioactive isotopes to deliver ionizing radiation directly to the tumour offering an accurate dose distribution with steep dose gradient between tumour and normal tissue. It has a longstanding tradition being used since 1960 ( $^{192}\text{Ir}$  wires) and 1979 ( $^{125}\text{I}$  seeds) [65,66]. Its use has been suggested as a treatment option for patients with newly diagnosed non-resectable, small ( $\leq 4$  cm), and circumscribed IDH-mutant grade 2 diffuse glioma in non-critical locations [67–71]. Temporary implants are typically preferred because of reduced risk of long-term toxicity compared to permanent implants [72]. The application of interstitial brachytherapy adds to the treatment portfolio if used in experienced hands and in selected cases (Delphi: no consensus [50 %]).

### Dose, fractionation, toxicity

Tumour grade is still utilized for the choice of prescription dose, primarily because grade 2 and grade 3 diffuse glioma were treated with different trials.

In grade 2 tumours, several clinical trials have failed to show a clear dose response relationship [44,73]. Therefore, 50.4 Gy in 28 fractions, as used in the EORTC 22033 trial [47], is recommended (Delphi: strong consensus [100 %]). As 54 Gy in 30 fractions was used in several trials including the RTOG 9802, the committee agreed that this dose level is

also acceptable [74] (Delphi: consensus [83.3 %]). A lower dose level such as 45 Gy in 25 fractions, used by some practitioners in the treatment of large tumours, is advised against (Delphi: strong consensus [100 %]) as the historical trials that investigated this dose followed prescription conventions (ICRU 29) that would result in a biologically lower dose today.

In grade 3 tumours, 59.4 Gy in 33 fractions has been frequently used in trials. This is considered the standard for grade 3 1p/19q non-codeleted tumours [75]. This fractionation was also used in two clinical trials of grade 3 oligodendroglioma [76,77] but there are no randomised trials comparing different dose and fractionation schedules in this group of patients. The committee discussed the potential to reduce this dose level to minimize late effects, especially since patients with grade 3 1p/19q codeleted tumours have a better long-term survival. Alternative fractionation schedules, such as 56 Gy in 28 fractions, 54–57.6 Gy in 30–32 fractions, or simultaneous integrated boost (SIB) giving 54 Gy to non-enhancing and 60 Gy to enhancing disease in 30 fractions, could be used at the discretion of the treating physician. Historically, 60 Gy in 30 fractions was used in several high-grade glioma trials that included both grade 3 and grade 4 tumours (IDH wildtype and IDH-mutant). This dose should not be exceeded in grade 3 tumours [78] (Delphi: strong consensus [100 %]).

### Discussion and future developments

Historically, trials investigating survival endpoints in lower grade diffuse glioma have taken ten years or more from trial initiation to yield clinically meaningful results. As such, basic concepts concerning target delineation and treatment dose have remained largely stable over the last decades. Use of response criteria such as those proposed by the Response Assessment in Neuro-Oncology group may allow for a faster introduction of new treatments into the clinic [13].

The number of imaging techniques, both from MRI and functional imaging, available for target delineation and response assessment is increasing and are likely to grow in importance in the coming years. As such, the complexity of target delineation may increase, and so will the added value of artificial intelligence assisted decision making. The successful application of targeted radionuclide therapy towards the treatment of extracranial tumours (such as neuroendocrine tumours and prostate cancer) has prompted efforts to translate this approach to neuro-oncology [79]. By exchanging the radionuclide, the same PET tracer can be used either for diagnostic purposes or therapy. For example, exchanging the positron emitter  $^{68}\text{Ga}$  or  $^{18}\text{F}$  used in diagnostics with a  $\beta^-$ -emitter such as  $^{177}\text{Lu}$  allows for targeted radionuclide therapy. A few clinical applications of targeted radionuclide therapy in glioma patients have passed the preclinical stage and are currently evaluated in clinical trials [80]. The outcomes of trials investigating survival, quality of life and neurocognitive function after proton beam therapy will determine its place in the radio therapeutic arsenal towards lower grade diffuse gliomas. In the future, ultra-high dose rate, or FLASH, radiotherapy may emerge as a treatment option. In high grade glioma, pre-clinical data suggests an opportunity for improving neurocognitive outcomes without compromising tumour control [81].

This guideline did not address the question of the optimal treatment sequence. The introduction of new systemic treatments may alter the timing of adjuvant radiotherapy after resection. For example, vorasidenib, an IDH1/2 inhibitor currently pending license approval, has been shown in a phase III trial to increase progression free survival in patients with grade 2 IDH-mutant diffuse glioma, which may delay the use of radiotherapy in patients [82]. Lastly, the increasing knowledge of biological markers has not yet been integrated into larger trials investigating dose and fractionation. The question whether the current dose levels are still necessary for good prognostic subgroups (like grade 3 IDH-mutant and 1p/19q codeleted tumours) therefore remains to be answered, and as such, it was felt that an allowance towards a dose reduction in such patients could not be made in this guideline.

## Conclusions and recommendations

This guideline provides recommendations for radiotherapy in *IDH-mutant* grade 2 and 3 diffuse glioma. Delineation should be informed by at least a directly acquired postoperative MRI. For grade 2 tumours, a 10 mm CTV margin and a dose of 50.4 Gy in 28 fractions is recommended. For grade 3 tumours, a 15 mm CTV and a dose of 59.4 Gy in 33 fractions is recommended. The guideline provides recommendations on OAR contouring, treatment planning, and discusses alternative methods of radiotherapy dose delivery.

## CRedit authorship contribution statement

**Brigitta G. Baumert:** Conceptualization, Methodology, Project administration, Writing – original draft, Writing – review & editing. **Jaap P. M. Jaspers:** Formal analysis, Investigation, Writing – original draft, Writing – review & editing. **Vera C. Keil:** Formal analysis, Investigation, Writing – original draft, Writing – review & editing. **Norbert Galldiks:** Investigation, Writing – original draft, Writing – review & editing. **Ewa Izzycka-Swieszevska:** Investigation, Writing – original draft, Writing – review & editing. **Beate Timmermann:** Investigation, Writing – original draft, Writing – review & editing. **Anca L. Grosu:** Investigation, Writing – review & editing. **Giuseppe Minniti:** Investigation, Writing – original draft, Writing – review & editing. **Umberto Ricardi:** Investigation, Writing – review & editing. **Frédéric Dhermain:** Investigation, Writing – review & editing. **Damien C. Weber:** Investigation, Writing – review & editing. **Martin van den Bent:** Writing – review & editing. **Roberta Rudà:** Writing – review & editing. **Maximilian Niyazi:** Investigation, Writing – original draft, Writing – review & editing. **Sara Erridge:** Formal analysis, Investigation, Writing – original draft, Writing – review & editing.

## Declaration of competing interest

MvdB: Receipt of grant/research support from Boehringer-Ingelheim, and receipt of honoraria or consultation fees from Boehringer-Ingelheim, Servier, Genenta, Nerviano, Incyte, Chimerix, Fore Biotherapeutics. Participated in a company sponsored speaker's bureau for Servier; NG: Receipt of grant/research support from German Research Council (project number 428090865/SPP 2177), and receipt of honoraria or consultation fees from Blue Earth Diagnostics, Telix Pharmaceuticals; GM: Receipt of grant/research support from Horizon EU-funded LEGATO-Trial, and receipt of honoraria or consultation fees from Servier, AstraZeneca, Novocure; VK: Receipt of grant/research support from Hanarth Stichting, and receipt of honoraria or consultation fees from Eli Lilly (Consultation fees). Bayer stock shareholder; MN: Receipt of grant/research support from Deutsche Krebshilfe (DKH), Brainlab AG, Elekta AB, and participated in a company sponsored speaker's bureau for AstraZeneca, Brainlab AG; SE: Receipt of honoraria or consultation fees from Servier; UR: Receipt of grant/research support from Institutional research grants from Brainlab, and receipt of honoraria or consultation fees from AstraZeneca, Accuray; RR: Receipt of grant/research support from Institutional research grants from Bayer, and receipt of honoraria or consultation fees from Novocure, Servier, Genenta, CureVac.

## Acknowledgement

In memoriam of our esteemed colleague, Dr. Frank Lagerwaard who passed away during working on this manuscript. We would like to deeply thank him for his contribution to this manuscript. The reviewing of the guideline was performed by Susan Short, Elizabeth Moyal and Steve Braunstein, whose advice and constructive comments were highly appreciated.

## Statement on funding

No funding has been received for the development of these guidelines.

## Disclaimer

ESTRO cannot endorse all statements or opinions made on the guidelines. Regardless of the vast professional knowledge and scientific expertise in the field of radiation oncology that ESTRO possesses, the Society cannot inspect all information to determine the truthfulness, accuracy, reliability, completeness or relevancy thereof. Under no circumstances will ESTRO be held liable for any decision taken or acted upon as a result of reliance on the content of the guidelines.

The component information of the guidelines is not intended or implied to be a substitute for professional medical advice or medical care. The advice of a medical professional should always be sought prior to commencing any form of medical treatment. To this end, all component information contained within the guidelines is done so for solely educational and scientific purposes. ESTRO and all of its staff, agents and members disclaim any and all warranties and representations with regards to the information contained on the guidelines. This includes any implied warranties and conditions that may be derived from the aforementioned guidelines.

## References

- [1] Louis DN, et al. The 2016 World Health Organization classification of tumors of the central nervous system: a summary. *Acta Neuropathol* 2016;131(6):803–20.
- [2] Louis DN, et al. The 2021 WHO classification of tumors of the central nervous system: a summary. *Neuro Oncol* 2021;23(8):1231–51.
- [3] Brat DJ, et al. Molecular biomarker testing for the diagnosis of diffuse gliomas. *Arch Pathol Lab Med* 2022;146(5):547–74.
- [4] Niyazi M, et al. ESTRO-EANO guideline on target delineation and radiotherapy details for glioblastoma. *Radiother Oncol* 2023;184.
- [5] Weller M, et al. EANO guidelines on the diagnosis and treatment of diffuse gliomas of adulthood. *Nat Rev Clin Oncol* 2021;18(3):170–86.
- [6] Paulson ES, et al. Consensus opinion on MRI simulation for external beam radiation treatment planning. *Radiother Oncol* 2016;121(2):187–92.
- [7] Regnery S, et al. High-resolution FLAIR MRI at 7 Tesla for treatment planning in glioblastoma patients. *Radiother Oncol* 2019;130:180–4.
- [8] Ellingson BM, et al. Consensus recommendations for a standardized brain tumor imaging protocol in clinical trials. *Neuro Oncol* 2015;17(9):1188–98.
- [9] Danielli L, et al. Brain tumor-enhancement visualization and morphometric assessment: a comparison of MPRAGE, SPACE, and VIBE MRI techniques. *AJNR Am J Neuroradiol* 2019;40(7):1140–8.
- [10] Putz F, et al. Magnetic resonance imaging for brain stereotactic radiotherapy : a review of requirements and pitfalls. *Strahlenther Onkol* 2020;196(5):444–56.
- [11] Castellano A, et al. Advanced imaging techniques for radiotherapy planning of gliomas. *Cancers* 2021;13(5):1063.
- [12] Capelle L, et al. Spontaneous and therapeutic prognostic factors in adult hemispheric World Health Organization Grade II gliomas: a series of 1097 cases: clinical article. *Journal of Neurosurgery JNS* 2013;118(6):1157–68.
- [13] Wen PY, et al. RANO 2.0: update to the response assessment in neuro-oncology criteria for high- and low-grade gliomas in adults. *J Clin Oncol* 2023;41(33):5187–99.
- [14] van West SE, et al. Incidence of pseudoprogression in low-grade gliomas treated with radiotherapy. *Neuro Oncol* 2017;19(5):719–25.
- [15] Ludmir EB, et al. Increased risk of pseudoprogression among pediatric low-grade glioma patients treated with proton versus photon radiotherapy. *Neuro Oncol* 2019;21(5):686–95.
- [16] Jaspers JPM, et al. Early and late contrast enhancing lesions after photon radiotherapy for IDH mutated grade 2 diffuse glioma. *Radiother Oncol* 2023;184:109674.
- [17] Harrabi SB, et al. Dosimetric advantages of proton therapy over conventional radiotherapy with photons in young patients and adults with low-grade glioma. *Strahlenther Onkol* 2016;192(11):759–69.
- [18] Davis AT, Palmer AL, Nisbet A. Can CT scan protocols used for radiotherapy treatment planning be adjusted to optimize image quality and patient dose? a systematic review. *Br J Radiol* 2017;90(1076):20160406.
- [19] Hutterer M, et al. [18F]-fluoro-ethyl-L-tyrosine PET: a valuable diagnostic tool in neuro-oncology, but not all that glitters is glioma. *Neuro Oncol* 2013;15(3):341–51.
- [20] Pichler R, et al. Is there a place for FET PET in the initial evaluation of brain lesions with unknown significance? *Eur J Nucl Med Mol Imaging* 2010;37(8):1521–8.
- [21] Jansen NL, et al. MRI-suspected low-grade glioma: is there a need to perform dynamic FET PET? *Eur J Nucl Med Mol Imaging* 2012;39(6):1021–9.



- [22] Ninatti G, et al. Preoperative [11C]methionine PET to personalize treatment decisions in patients with lower-grade gliomas. *Neuro Oncol* 2022;24(9):1546–56.
- [23] Galldiks N, et al. Photopenic defects on O-(2-[18F]-fluoroethyl)-L-tyrosine PET: clinical relevance in glioma patients. *Neuro Oncol* 2019;21(10):1331–8.
- [24] Zaragori T, et al. Photopenic defects in gliomas with amino-acid PET and relative prognostic value: a multicentric 11C-methionine and 18F-FDOPA PET experience. *Clin Nucl Med* 2021;46(1):e36–7.
- [25] Kracht LW, et al. Delineation of brain tumor extent with [11C]L-methionine positron emission tomography: local comparison with stereotactic histopathology. *Clin Cancer Res* 2004;10(21):7163–70.
- [26] Pauleit D, et al. O-(2-[18F]fluoroethyl)-L-tyrosine PET combined with MRI improves the diagnostic assessment of cerebral gliomas. *Brain* 2005;128(Pt 3):678–87.
- [27] Pafundi DH, et al. Biopsy validation of 18F-DOPA PET and biodistribution in gliomas for neurosurgical planning and radiotherapy target delineation: results of a prospective pilot study. *Neuro Oncol* 2013;15(8):1058–67.
- [28] Roodakker KR, et al. Region-by-region analysis of PET, MRI, and histology in en bloc-resected oligodendrogliomas reveals intra-tumoral heterogeneity. *Eur J Nucl Med Mol Imaging* 2019;46(3):569–79.
- [29] Verburg N, et al. Improved detection of diffuse glioma infiltration with imaging combinations: a diagnostic accuracy study. *Neuro Oncol* 2020;22(3):412–22.
- [30] Schön S, et al. Imaging glioma biology: spatial comparison of amino acid PET, amide proton transfer, and perfusion-weighted MRI in newly diagnosed gliomas. *Eur J Nucl Med Mol Imaging* 2020;47(6):1468–75.
- [31] Galldiks N, et al. Contribution of PET imaging to radiotherapy planning and monitoring in glioma patients - a report of the PET/RANO group. *Neuro Oncol* 2021;23(6):881–93.
- [32] Law I, et al. Joint EANM/EANO/RANO practice guidelines/SNMMI procedure standards for imaging of gliomas using PET with radiolabelled amino acids and [(18F)FDG]: version 1.0. *Eur J Nucl Med Mol Imaging* 2019;46(3):540–57.
- [33] Ferracci F-X, Michaud K, Duffau H. The landscape of postsurgical recurrence patterns in diffuse low-grade gliomas. *Crit Rev Oncol Hematol* 2019;138:148–55.
- [34] Fukuya Y, et al. Tumor recurrence patterns after surgical resection of intracranial low-grade gliomas. *J Neurooncol* 2019;144(3):519–28.
- [35] Jakola AS, et al. Spatial distribution of malignant transformation in patients with low-grade glioma. *J Neurooncol* 2020;146(2):373–80.
- [36] Pu AT, et al. Low grade gliomas: preliminary analysis of failure patterns among patients treated using 3D conformal external beam irradiation. *Int J Radiat Oncol Biol Phys* 1995;31(3):461–6.
- [37] Rudoler S, et al. Patterns of tumor progression after radiotherapy for low-grade gliomas: analysis from the computed tomography/magnetic resonance imaging era. *Am J Clin Oncol* 1998;21(1):23–7.
- [38] van den Bent MJ, et al. Long-term efficacy of early versus delayed radiotherapy for low-grade astrocytoma and oligodendroglioma in adults: the EORTC 22845 randomised trial. *Lancet* 2005;366(9490):985–90.
- [39] Shaw E, et al. Prospective randomized trial of low- versus high-dose radiation therapy in adults with supratentorial low-grade glioma: initial report of a North Central Cancer Treatment Group/Radiation Therapy Oncology Group/Eastern Cooperative Oncology Group study. *J Clin Oncol* 2002;20(9):2267–76.
- [40] Kamran SC, et al. Patterns of failure among patients with low-grade glioma treated with proton radiation therapy. *Pract Radiat Oncol* 2019;9(4):e356–61.
- [41] Jaspers JPM, et al. Pattern of failure in IDH mutated, low grade glioma after radiotherapy - Implications for margin reduction. *Radiother Oncol* 2021;156:43–8.
- [42] Back M, et al. Pattern of failure in anaplastic glioma patients with an IDH1/2 mutation Rezidivmuster bei Patienten mit anaplastischem Glioma mit einer IDH1/2-Mutation. *Strahlenther Onkol* 2020;196(1):31–9.
- [43] Im JH, et al. Recurrence patterns after maximal surgical resection and postoperative radiotherapy in anaplastic gliomas according to the new 2016 WHO classification. *Sci Rep* 2018;8(1):777.
- [44] Karim AB, et al. A randomized trial on dose-response in radiation therapy of low-grade cerebral glioma: European Organization for Research and Treatment of Cancer (EORTC) Study 22844. *Int J Radiat Oncol Biol Phys* 1996;36(3):549–56.
- [45] Shaw EG, et al. Randomized trial of radiation therapy plus procarbazine, lomustine, and vincristine chemotherapy for supratentorial adult low-grade glioma: initial results of RTOG 9802. *J Clin Oncol* 2012;30(25):3065–70.
- [46] Fisher BJ, et al. Phase 2 Study of temozolomide-based chemoradiotherapy for high-risk low-grade gliomas: preliminary results of radiation therapy oncology group 0424. *Int J Radiat Oncol \*Biol \*Phys* 2015;91(3):497–504.
- [47] Baumert BG, et al. Temozolomide chemotherapy versus radiotherapy in high-risk low-grade glioma (EORTC 22033–26033): a randomised, open-label, phase 3 intergroup study. *Lancet Oncol* 2016;17(11):1521–32.
- [48] Intergroup Radiation Therapy Oncology Group Trial 9402., et al., Phase III trial of chemotherapy plus radiotherapy compared with radiotherapy alone for pure and mixed anaplastic oligodendroglioma: Intergroup Radiation Therapy Oncology Group Trial 9402. *J Clin Oncol*. 2006. 24(18): p. 2707–14.
- [49] van den Bent MJ, et al. Adjuvant procarbazine, lomustine, and vincristine improves progression-free survival but not overall survival in newly diagnosed anaplastic oligodendrogliomas and oligoastrocytomas: a randomized European Organisation for Research and Treatment of Cancer phase III trial. *J Clin Oncol* 2006;24(18):2715–22.
- [50] van den Bent MJ, et al. Interim results from the CATNON trial (EORTC study 26053–22054) of treatment with concurrent and adjuvant temozolomide for 1p/19q non-co-deleted anaplastic glioma: a phase 3, randomised, open-label intergroup study. *Lancet* 2017;390(10103):1645–53.
- [51] Wick W, et al. NOA-04 randomized phase III trial of sequential radiochemotherapy of anaplastic glioma with procarbazine, lomustine, and vincristine or temozolomide. *J Clin Oncol* 2009;27(35):5874–80.
- [52] Cubillos Mesías M, et al. Quantification and assessment of interfraction setup errors based on cone beam CT and determination of safety margins for radiotherapy. *PLoS One* 2016;11(3):e0150326.
- [53] Eekers DBP, et al. Update of the EPTN atlas for CT- and MR-based contouring in Neuro-Oncology. *Radiother Oncol* 2021;160:259–65.
- [54] Eekers DB, et al. The EPTN consensus-based atlas for CT- and MR-based contouring in neuro-oncology. *Radiother Oncol* 2018;128(1):37–43.
- [55] Brouwer CL, et al. CT-based delineation of organs at risk in the head and neck region: DAHANCA, EORTC, GORTEC, HKNPCSG, NCIC CTG, NCRI, NRG Oncology and TROG consensus guidelines. *Radiother Oncol* 2015;117(1):83–90.
- [56] Lambrecht M, et al. Radiation dose constraints for organs at risk in neuro-oncology; the European particle therapy network consensus. *Radiother Oncol* 2018;128(1):26–36.
- [57] Langendijk JA, et al. Selection of patients for radiotherapy with protons aiming at reduction of side effects: the model-based approach. *Radiother Oncol* 2013;107(3):267–73.
- [58] Gaito S, et al. Normal tissue complication probability modelling for toxicity prediction and patient selection in proton beam therapy to the central nervous system: a literature review. *Clin Oncol (R Coll Radiol)* 2022;34(6):e225–37.
- [59] Gondi V, et al. Preservation of memory with conformal avoidance of the hippocampal neural stem-cell compartment during whole-brain radiotherapy for brain metastases (RTOG 0933): a phase II multi-institutional trial. *J Clin Oncol* 2014;32(34):3810–6.
- [60] Dworkin M, et al. Increase of pseudoprogression and other treatment related effects in low-grade glioma patients treated with proton radiation and temozolomide. *J Neurooncol* 2019;142(1):69–77.
- [61] Eichkorn T, et al. Analysis of safety and efficacy of proton radiotherapy for IDH-mutated glioma WHO grade 2 and 3. *J Neurooncol* 2023;162(3):489–501.
- [62] Stock A, et al. Pseudoprogression is frequent following front-line radiotherapy in pediatric low-grade glioma - results from the German LGG cohort. *Int J Radiat Oncol Biol Phys* 2021.
- [63] Ek H, et al. Transitioning from conventional photon therapy to proton therapy for primary brain tumors. *Acta Oncol* 2023;62(4):391–9.
- [64] Willmann J, Leiser D, Weber DC. Oncological outcomes, long-term toxicities, quality of life and sexual health after pencil-beam scanning proton therapy in patients with low-grade glioma. *Cancers (Basel)* 2023;15(21).
- [65] Munding F, et al. Stereotactic treatment of brain lesions. Biopsy, interstitial radiotherapy (iridium-192 and iodine-125) and drainage procedures. *Appl Neurophysiol* 1980;43(3–5):198–204.
- [66] Bernstein M, Gutin PH. Interstitial irradiation of brain tumors: a review. *Neurosurgery* 1981;9(6):741–50.
- [67] Schwarz SB, et al. Iodine-125 brachytherapy for brain tumours—a review. *Radiat Oncol* 2012;7:30.
- [68] Ruge MI, et al. Stereotactic brachytherapy with iodine-125 seeds for the treatment of inoperable low-grade gliomas in children: long-term outcome. *J Clin Oncol* 2011;29(31):4151–9.
- [69] Suchorska B, et al. Stereotactic brachytherapy for low-grade cerebral glioma after tumor resection. *Neuro Oncol* 2011;13(10):1133–42.
- [70] Choi M, Zabramski JM. Re-irradiation using brachytherapy for recurrent intracranial tumors: a systematic review and meta-analysis of the literature. *Cureus* 2020;12(8):e9666.
- [71] Watson J, et al. Long-term outcome of stereotactic brachytherapy with temporary Iodine-125 seeds in patients with WHO grade II gliomas. *Radiat Oncol* 2020;15(1):275.
- [72] Ruge MI, et al. Stereotactic iodine-125 brachytherapy for brain tumors: temporary versus permanent implantation. *Radiat Oncol* 2012;7:94.
- [73] Breen WG, et al. Final report from Intergroup NCTG 86-72-51 (Alliance): a phase III randomized clinical trial of high-dose versus low-dose radiation for adult low-grade glioma. *Neuro Oncol* 2020;22(6):830–7.
- [74] Buckner JC, et al. Radiation plus procarbazine, CCNU, and vincristine in low-grade glioma. *N Engl J Med* 2016;374(14):1344–55.
- [75] van den Bent MJ, et al. Adjuvant and concurrent temozolomide for 1p/19q non-co-deleted anaplastic glioma (CATNON; EORTC study 26053–22054): second interim analysis of a randomised, open-label, phase 3 study. *Lancet Oncol* 2021;22(6):813–23.
- [76] Cairncross G, et al. Phase III trial of chemoradiotherapy for anaplastic oligodendroglioma: long-term results of RTOG 9402. *J Clin Oncol* 2013;31(3):337–43.
- [77] van den Bent MJ, et al. Adjuvant procarbazine, lomustine, and vincristine chemotherapy in newly diagnosed anaplastic oligodendroglioma: long-term follow-up of EORTC brain tumor group study 26951. *J Clin Oncol* 2013;31(3):344–50.
- [78] Wick W, et al. Long-term analysis of the NOA-04 randomized phase III trial of sequential radiochemotherapy of anaplastic glioma with PCV or temozolomide. *Neuro Oncol* 2016;18(11):1529–37.
- [79] Tolboom N, et al. Theranostics in neurooncology: heading toward new horizons. *J Nucl Med* 2024;65(2):167–73.
- [80] Galldiks N, et al. PET imaging of gliomas: Status quo and quo vadis? *Neuro Oncol* 2024;6:noae078. <https://doi.org/10.1093/neuonc/noae078>.
- [81] Montay-Gruel P, et al. Hypofractionated FLASH-RT as an effective treatment against glioblastoma that reduces neurocognitive side effects in mice. *Clin Cancer Res* 2021;27(3):775–84.



- [82] Mellinghoff IK, et al. Vorasidenib in IDH1- or IDH2-mutant low-grade glioma. *N Engl J Med* 2023;389(7):589–601.
- [83] Buckner JC, et al. Phase II trial of procarbazine, lomustine, and vincristine as initial therapy for patients with low-grade oligodendroglioma or oligoastrocytoma: efficacy and associations with chromosomal abnormalities. *J Clin Oncol* 2003;21(2):251–5.
- [84] Fisher BJ, et al. Phase 2 study of a temozolomide-based chemoradiation therapy regimen for high-risk, low-grade gliomas: long-term results of radiation therapy oncology group 0424. *Int J Radiat Oncol Biol Phys* 2020;107(4):720–5.
- [85] Chang S, et al. Phase III randomized study of radiation and temozolomide versus radiation and nitrosourea therapy for anaplastic astrocytoma: results of NRG Oncology RTOG 9813. *Neuro Oncol* 2017;19(2):252–8.
- [86] Jaeckle KA, et al. CODEL: phase III study of RT, RT + TMZ, or TMZ for newly diagnosed 1p/19q codeleted oligodendroglioma. Analysis from the initial study design. *Neuro Oncol* 2021;23(3):457–67.