

Cytoarchitectonic and receptorarchitectonic organization in Broca's region and surrounding cortex

Karl Zilles^{1,2} and Katrin Amunts^{1,3}



Broca's region was originally described as a cortical site in the inferior frontal gyrus, where speech impairment occurs after brain lesions. However, this clinico-pathological definition does not define the underlying microstructural correlates. Two cytoarchitectonic areas (BA44, BA45) were identified as correlates of Broca's region in the inferior frontal opercular and triangular parts, respectively. Recent microstructural analyses based on the distribution of transmitter receptors suggest a further segregation of BA44 and BA45 and the inclusion of neighboring areas in the adjacent inferior frontal and precentral sulci as well as in the frontal operculum as structural correlates of Broca's region. Here, we review these recent cytoarchitectonic and receptorarchitectonic findings in Broca's region, and compare them with functional imaging data containing sufficient topographical specifications. Finally, Broca's region of the human brain is compared with the homologue region in the brain of apes, baboon and macaque monkey.

Addresses

¹ Institute of Neuroscience and Medicine INM-1, Research Centre Jülich, Jülich, Germany

² Department of Psychiatry, Psychotherapy and Psychosomatics, Medical Faculty, RWTH Aachen University, Aachen, Germany

³ C. & O. Vogt Institute for Brain Research, University Hospital Düsseldorf, Heinrich Heine University Düsseldorf, Germany

Corresponding author: Zilles, Karl (k.zilles@fz-juelich.de)

Current Opinion in Behavioral Sciences 2018, 21:93–105

This review comes from a themed issue on **The evolution of language**

Edited by **Christopher Petkov** and **William Marslen-Wilson**

<https://doi.org/10.1016/j.cobeha.2018.02.011>

2352-1546/© 2018 The Authors. Published by Elsevier Ltd. This is an open access article under the CC BY license (<http://creativecommons.org/licenses/by/4.0/>).

Introduction

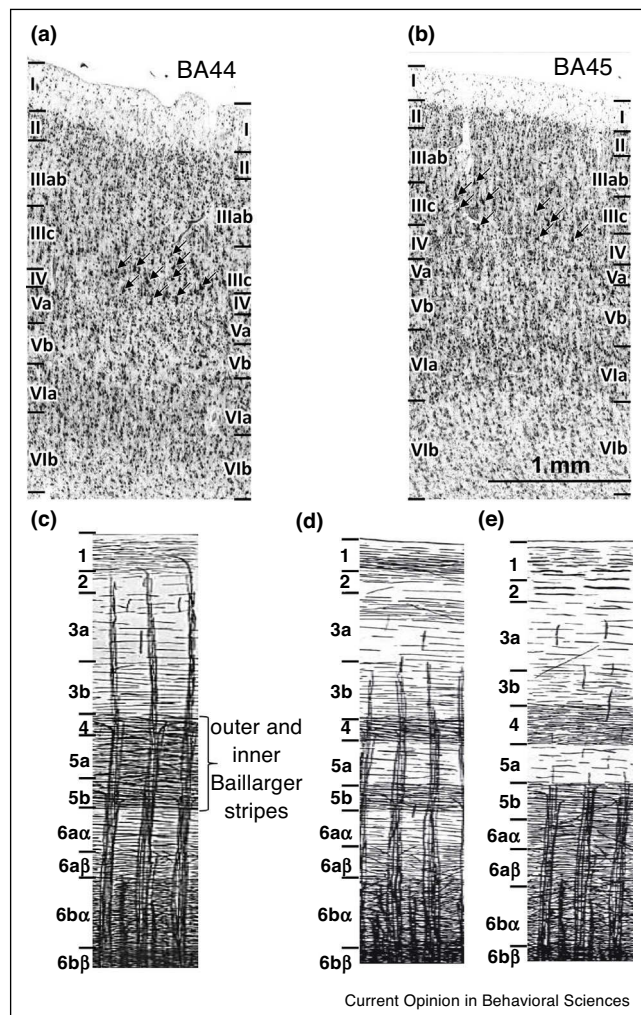
Broca [1,2] identified a cortical lesion site in the left inferior frontal gyrus of a stroke patient who could only repetitively speak the syllable 'Tan-tan'. Broca coined the term 'aphemia' for this functional deficit. The lesion site was later called Broca's region. Observations in additional patients with similar or different speech disturbances and localizations of the lesion confirmed his initial reports [3]. Dronkers *et al.* [4] could study this historical brain. The images show that the lesion site did

not only involve the gray matter of the posterior portion of the inferior frontal cortex, but also the underlying white matter as well as major parts of the basal ganglia and neighboring cortices. It became also clear, that the original concept of Broca's region cannot elucidate the relationship between a lesion of well-defined cortical areas and specific speech deficits; for review of the Broca's concept and its clinical-anatomical correlations (see Keller *et al.* [5] and Tremblay and Dick [6]). In addition to clinical data, neuroimaging studies in healthy subjects had to be used for understanding the functional segregation in Broca's region by addressing more specific speech and language processes. The scope of the present review is to focus on recent cytoarchitectonic and receptorarchitectonic findings in Broca's region, which reveal a previously underestimated degree of segregation, and to compare these findings with functional data.

The classical cytoarchitectonic concept of Broca's region

Brodmann [7] identified two cytoarchitectonic areas, BA44 and BA45, in Broca's region, which occupied the opercular and triangular parts of the inferior frontal gyrus, respectively. The posterior border of BA 44 is at the level of the ventral part of the precentral sulcus. BA44 and BA45 are often, but not always, separated by the ascending ramus of the Sylvian fissure. Since this ramus and other sulci of Broca's region are highly variable [8,9], the border between both areas cannot reliably be defined based on sulcal patterns. Similarly, the horizontal branch of the lateral fissure does not provide a consistent landmark for the ventral border of BA45 [10,11]. Brodmann [7] stated — without providing a detailed description — that BA47 of the orbital part of the inferior frontal gyrus shares various cytoarchitectonic features with BA44 and BA45, and thus summarized BA44, BA45 and BA47 under the term 'subfrontal subregion'. Therefore, BA47 may be a candidate for inclusion in Broca's region [12], which seems to be supported by its involvement in semantic encoding, attention to semantic relations, semantic relative to perceptual judgments, syntax, affective prosody, single word reading, and phonology [13–18]. However, we must keep in mind that Brodmann's map represents a two-dimensional drawing of the surface of a brain, and did not provide any microstructural segregation within the deep sulci. Thus, the intra-sulcal surface may be occupied by previously undefined areas. Additionally, anatomical and neuroimaging

Figure 1



Cytoarchitecture and myeloarchitecture of cortical areas in Broca's region. (a) Cytoarchitecture of BA44. Note the clusters of very large pyramidal cells in layer IIIc (arrows). Modified after Amunts *et al.* [26**]. (b) Cytoarchitecture of BA45. Note the clusters of very large pyramidal cells in layer IIIc (arrows). Modified after Amunts *et al.* [26**]. (c) Most common myeloarchitectonic feature in Broca's region. The myeloarchitectonic areas 56–59 and 53 are found within the extension of the cytoarchitectonic areas BA44, BA45 and BA47, and were myeloarchitectonically classified as unistriate or bistriate areas. In the unistriate areas, the outer and inner Baillarger stripes are not separate structures, but confluent and detectable as a single broad and myelinated stripe at the level of the myeloarchitectonic layers 4–5b. Delineations of the different areas within the unistriate cortex were recognized as variations of this basic type. The unistriate area 57 is comparable to the antero-dorsal part of BA44, whereas the unistriate areas 58–59 are comparable to BA45. (d) Myeloarchitecture of the bistriate area 56 (comparable to the posterior part of BA44) of Broca's region. The bistriate regions of the isocortex are characterized by the outer and inner Baillarger stripes visible as separate structures at the level of the myeloarchitectonic layer 4 and 5b, respectively. Parts of the myeloarchitectonic area 53 may correspond to BA47. (e) Common myeloarchitectonic features of areas 39–43 on the precentral gyrus. These areas were myeloarchitectonically classified as parts of the unistriate region of isocortex, that is, only the outer Baillarger stripe is visible at the level

of the myeloarchitectonic layer 4. All myeloarchitectonic illustrations are modified after Vogt [27*].

studies provide evidence of a heterogeneity within BA47. A recent study employed resting-state functional connectivity and data-driven modularity optimization [19]. Previous cytoarchitectonic studies also resulted in a more complex segregation of this brain region [20–22].

von Economo and Koskinas [23**] identified three cytoarchitectonic areas, which are completely or partly found on the inferior frontal gyrus. Their area FCB_m corresponds to BA44, area FDF to BA45, and area FF to BA47 [24]. The dysgranular area FCB_m is located between the agranular premotor cortex and the granular prefrontal areas. It has large pyramidal cells in the deeper part of layer III (Figure 1), an inconspicuous layer IV (dysgranular isocortex), a layer V which can be further subdivided by a higher cell packing density in its upper than lower part, and a lacking sharp border between layer VI and the white matter. The cortical ribbon of FDF is thinner than that of FCB_m , but contains even larger pyramidal cells in deeper layer III (addressed by the Greek letter Γ in its name, which points to the size — ‘giganto’ meaning very large — of layer III pyramids; Figure 1), a distinct layer IV (granular isocortex), as well as prominent cell columns. In area FF , layers V and VI are wider than in FDF , layer IV is thin, and all layers are less cell-dense than in FD [23**]. Particularly, the part of BA47 which adjoins BA45 is a typical granular cortex with a well-developed layer IV, but moving to the orbital part of BA47 layer IV becomes less distinct. This suggests that BA 47 can be further segregated. Finally, BA47 largely differs from BA44 and BA45 by lacking very large pyramids in deeper layer III, and by its receptor fingerprint (see below). Semantic processing leads to activations in areas of the left ifs and in BA47 [25].

Present concepts of the microstructure of Broca's region and its relationship to brain function

BA44 and BA45 are distinct from surrounding areas mainly by the presence of large pyramidal cells in deep layer III and in layer V (Figure 1). Furthermore, both areas show a lower cell packing density in layer VI. BA44 can be delineated from BA45 due to differences in layer IV: layer IV in BA44 is thin and invaded by pyramidal cells from neighboring layers III and V; that is, BA44 is ‘dysgranular’. Layer IV is clearly visible in BA45; that is, it is called ‘granular’ [26**]. The dysgranular appearance of BA44 clearly separates it from granular cortical areas like BA45 and lateral prefrontal areas.

The classical cytoarchitectonic maps of Broca's region [7*,23**] were supplemented in the first half of the last

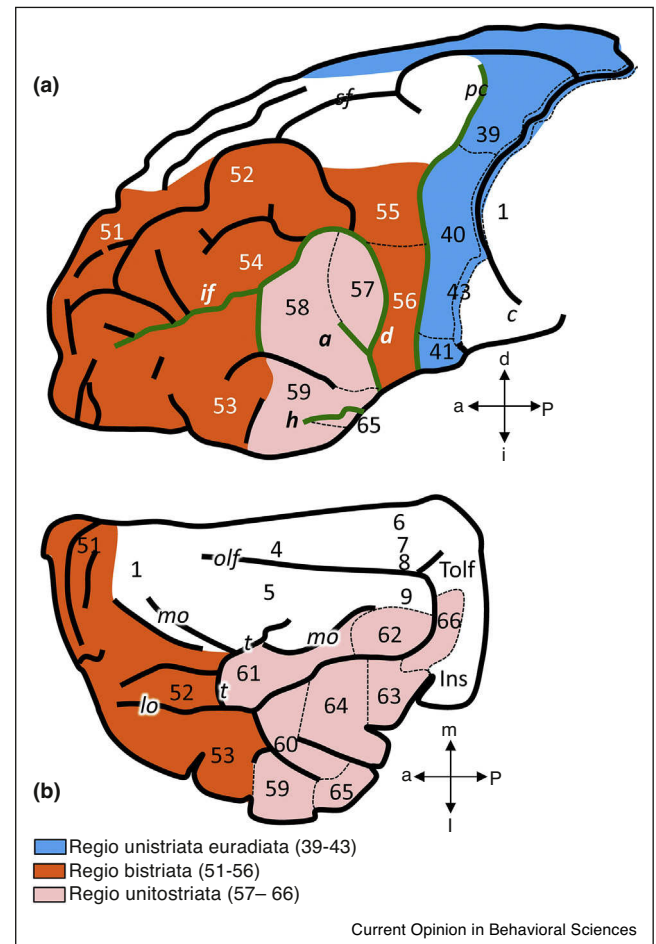
century by myeloarchitectonic observations, resulting in more fine-grained parcellations. Vogt [27] and Riegele [28] identified several areas in Broca's region. This was confirmed in later observations [29–32]. The myeloarchitectonic areas 56–57 cover the Pars opercularis, and were classified as members of the bistriate (area 56) or unistriate (area 57) group of isocortical areas in the frontal lobe. The unistriate areas 58–59 found in the Pars triangularis are comparable to BA45. The bistriate area 53 may correspond to parts of BA47 (Figure 2). The unistriate area 41 and ventral parts of area 40 match the position of the oro-facial region, which are comparable to the ventral part of Brodmann's area 6 [7].

BA44 can further be subdivided into an antero-dorsal (44d) and a ventro-posterior (44v) part based on mapping of receptors for neurotransmitters [41], and functional neuroimaging studies. The dorsal part of left BA44, which seems to correspond to 44d, was shown to be involved in phonological processing during acoustic presentations of single phonemes [33]. Phonological decoding in both hemispheres would then occur via callosal connections [34]. Another study demonstrated that 45a and 45p are differentially involved in sentence processing [35], thus supporting the notion of cortical segregation within BA45. Areas of Broca's region are central for processing syntactic dependencies between elements of a sentence [36]. Decisions on syntactic properties of single words result in activations of the left BA44 and BA45 [37], which may be caused by challenging the syntactic working memory [38]. Both areas are also required in prosodic decoding [39,40]. Sign language leads to an activation of the left BA45 [41]. Left BA45 is more extensively activated than left BA44 if words must be selected and generated belonging to semantic categories compared to over-learned words, which would not require a major semantic effort [42]. The semantic processing in BA45 is also supported by the finding that the left BA45 is more involved in semantic processing than the left BA44, which is more active in syntactic processing [43]. An extension of Broca's region beyond the opercular and triangular parts of the inferior frontal gyrus in the light of functional data was discussed as well [44,45].

The multimodal investigation of the distribution patterns of multiple receptors and cytoarchitecture points into the same direction [46,47]. New areas were identified at the junction of the inferior frontal sulcus (if) and the ventral precentral sulcus (pci), where premotor area BA6 is located.

It was also suggested that the orofacial part of the ventral precentral gyrus extending posteriorly to the anterior subcentral sulcus belongs to Broca's region [48,49,50]. This region contains areas overlapping with parts of the premotor cortex, and eventually the primary motor cortex (BA4) [46,47]. Ventro-caudal area 6VC resembles FB,

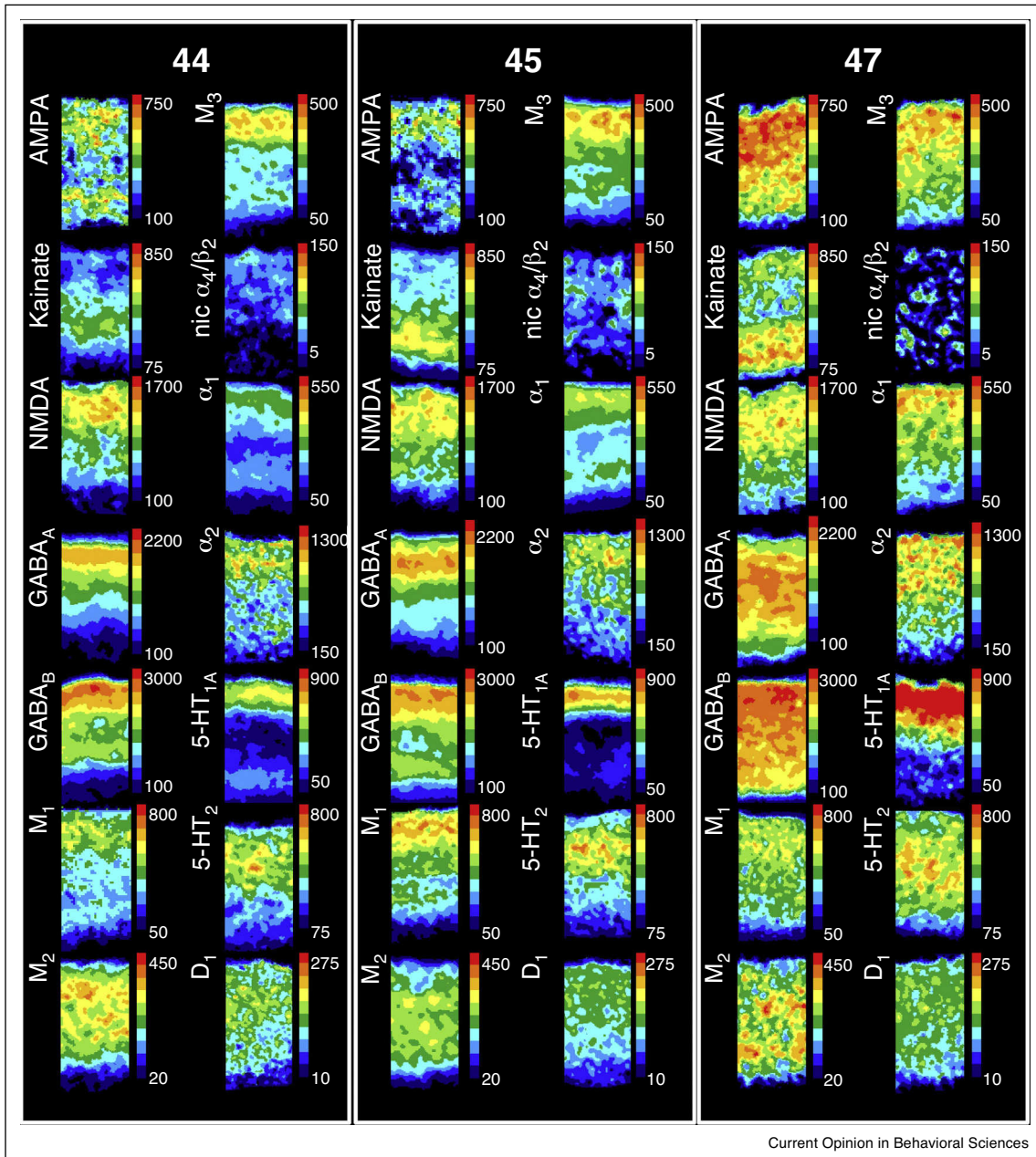
Figure 2



Myeloarchitectonic map of the frontal lobe in lateral (a) and basal (b) views. Myeloarchitectonic areas 56 and 57 are comparable to BA44, areas 58 and 59 to BA45, area 53 to BA47, areas 41 and ventral parts of 40 to the oro-facial part of the premotor cortex, and areas 60–66 belong to the opercular and fronto-orbital regions. It is not clear which areas of the latter group are parts of the functionally defined Broca region. a, ascending branch of the lateral fissure; d, diagonal sulcus; h, horizontal branch of the lateral fissure; if, inferior frontal sulcus; Ins, insular cortex; lo, lateral orbital sulcus; mo, medial orbital sulcus; olf, olfactory sulcus; pc, precentral sulcus; sf, superior frontal sulcus, Tolf, Tuberculum olfactorium, t, transverse orbital sulcus.

and ventro-rostral area 6VR FA of von Economo and Koskinas [23]. The orofacial part of the agranular BA4 contains much smaller Betz cells than its hand and trunk representation, while the agranular BA6 does not contain Betz cells. The orofacial part of the premotor cortex has been identified more than 70 years ago using functional observations during surgery [51,52]. The role of the premotor cortex for planning of speech and categorization was later supported by functional imaging observations and intraoperative mapping [53,54]. The premotor cortex also contributes to expressive language [55]. The left the premotor cortex of right-handers and

Figure 3



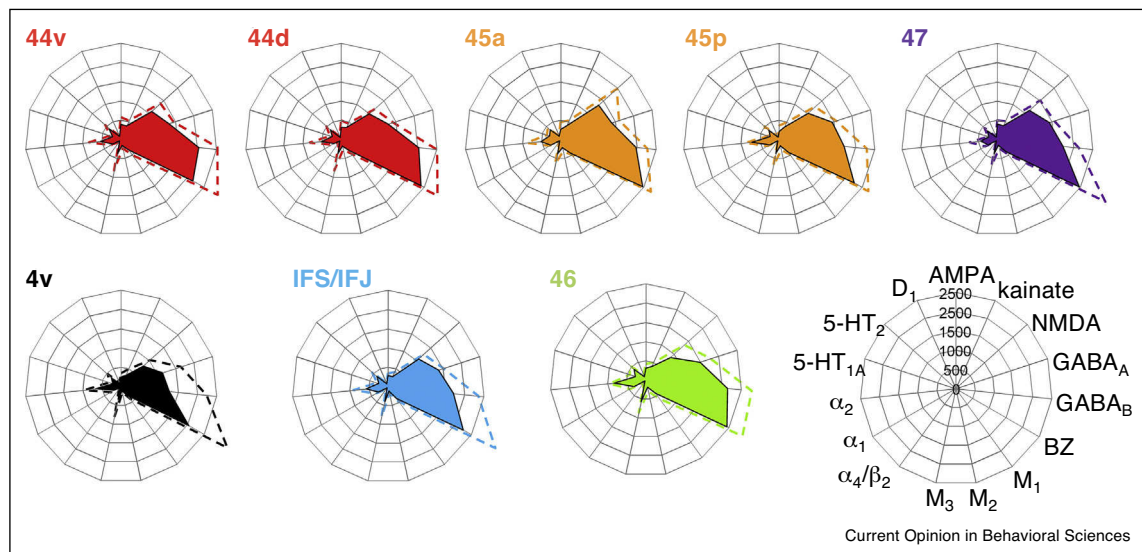
Laminar distributions of 14 receptor types in areas BA44, BA45, and BA47 from cortical surface (top) to the white matter border (bottom). Color coded receptor autoradiographs visualize the laminar distribution of the concentrations of glutamate (AMPA, kainate, NMDA, mGluR2/3), GABA (GABA_A, GABA_B), acetylcholine (M₁, M₂, M₃, nicotinic α_4/β_2), norepinephrine (α_1 , α_2), serotonin (5-HT_{1A}, 5-HT₂) and dopamine (D₁) receptors in 8 of the 26 examined brain areas. Color coding indicates receptor densities in fmol/mg protein. Modified after [61*,111*].

the right the premotor cortex of left-handers are activated during lexical decisions on manual-action verbs like ‘grasp’ or ‘throw’, indicating a representation of action verb semantics from an egocentric perspective [56]. It has been suggested that understanding of nouns for graspable objects requires ‘body-based’ experience [57*], and similar neural mechanisms as those enabling grasping [58].

Thus, processing of those nouns seems to engage classical Broca areas and the premotor cortex.

Similar to other brain regions [59*,60], the inferior frontal gyrus shows a highly differentiated regional and laminar distribution of multiple transmitter receptors (Figure 3). Multi-receptor fingerprints, indicating the interrelationship

Figure 4



(Upper part) Receptor fingerprints and standard deviations (averaged over eight human hemispheres) of areas 44v, 44d, 45a, 45p, BA46, BA47, 4v (primary motor cortex in the facial representation region), and the IFJ/IFS region. Receptor types and sequence in the polar plots see scheme in the lower row. Modified after [61**,111*]. **(Lower part)** Hierarchical cluster analysis of the fingerprints of 26 cortical areas. Modified after [61**]. The fingerprints of areas in the core of Broca's region (44d, 44v, 45a, 45p) and BA47, as well as of the sulcal region IFJ/IFS, area 4v of the facial representation of the primary motor cortex, and the areas Te2 (auditory belt region) and pSTG (posterior part of the superior temporal gyrus) form the cluster of 'language related' areas [61**]. This cluster differs from the areas of the inferior parietal cortex (PGa, PGp, PF, PFcm, PFm, PFop, PFt; data from [112], primary sensory cortices (3b primary somatosensory cortex, Te1 primary auditory cortex, V1 primary visual cortex [113], cingulate cortex (BA32), prefrontal cortex (BA9, BA46), and higher visual cortex (FG1, FG2 [114]).

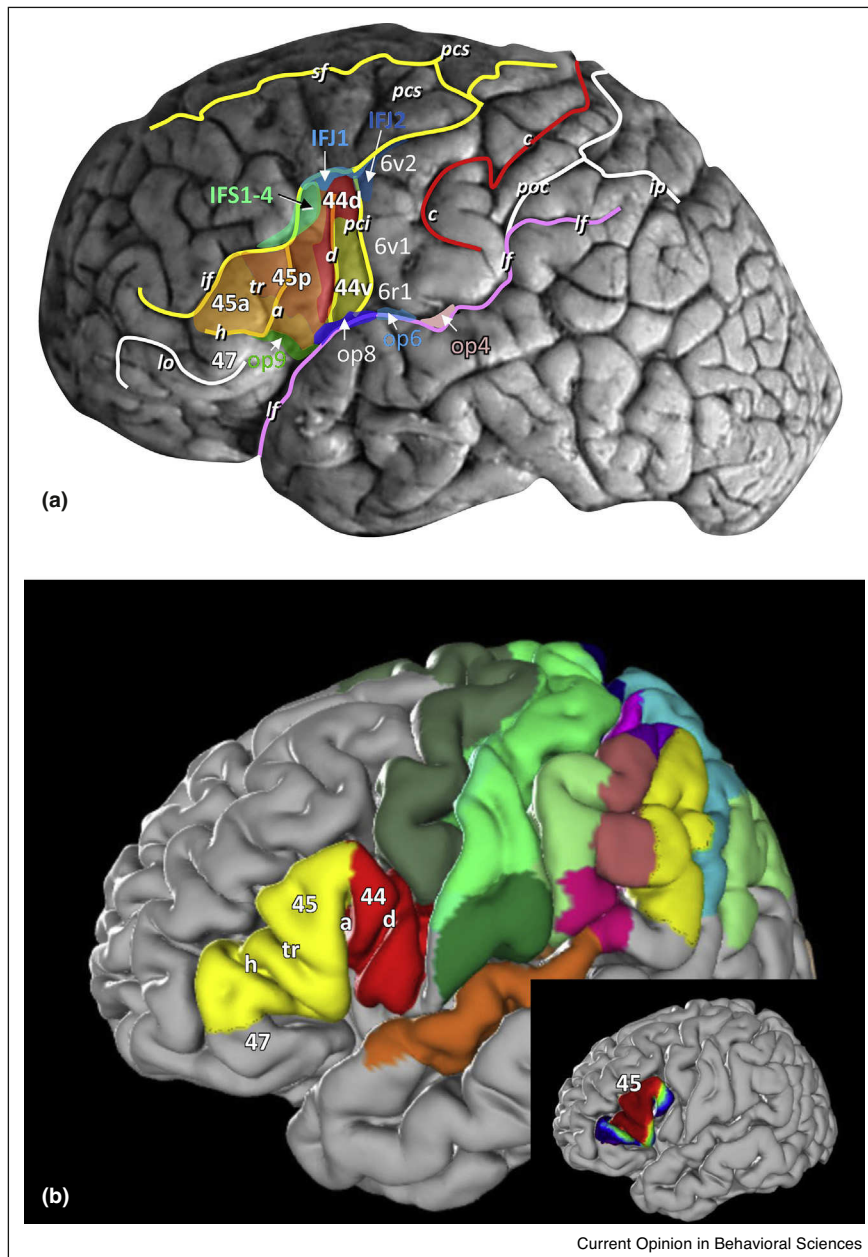
of receptor concentrations for different neurotransmitters in various areas, show a relatively high degree of similarity of areas involved in language processing [59*], but also point to differences in signal processing in each area (Figure 4). The fingerprints also suggest the subdivision of BA44 and BA45. They allow to identify laminar receptor concentrations of those receptors, which most contribute to the subdivisions. For example, there is a lower concentration of 5-HT₂ receptors in 44d than in 44v, while other receptors show similar concentrations. BA45 consists of an anterior (45a) and a posterior (45p) part with higher mean (averaged over all cortical layers) concentrations of some glutamate, GABA, acetylcholine and serotonin receptors in 45a than 45p [46**]. AMPA receptor concentrations are higher in the supragranular layers, and those of α_1 receptors in the deeper layers of 44d than 45p [46**]. Furthermore, 45a differs from the dorsally located prefrontal area BA46 by lower AMPA and GABA_A, but higher NMDA and M₂ receptor densities [61**].

BA47 differs from BA44 and BA45 by higher concentrations of AMPA, kainate, GABA_A, GABA_B, α_1 , α_2 , and particularly 5-HT_{1A} receptors at the orbitofrontal part of the inferior frontal gyrus receptors (Fig. 3). The fingerprints of ifs and ifj areas are more similar to that of 45p than to those of 44v, 44d, 45a and BA47 as shown by a hierarchical cluster analysis (Figure 4). Whereas nearly all

receptors reach highest concentrations in layers II–IV of all these areas, the glutamatergic kainate and nicotinic α_4/β_2 have their maxima in layers V–VI or layer IV, respectively. BA44 and 45 are separated by ifs from prefrontal areas BA 46, 8 and 9 [7*].

The ifs has often been interpreted as a landmark between the functionally distinct ventro-lateral prefrontal cortex including Broca's region, and the dorso-lateral prefrontal cortex. However, multi-receptor analysis and fMRI studies challenge the concept of a simple bi-partition of the prefrontal cortex. Novel areas (areas ifj1 and ifj 2) were detected at the junction of the inferior frontal with the precentral sulcus, and within the adjacent inferior frontal sulcus (areas ifs1 to ifs4) in a multi-receptor study [46**,62]. Areas ifj1 and ifj2 neighbor 44d, and are also dysgranular in their cytoarchitecture. Ventro-posteriorly, 44v has a border with the premotor area 6v1 (Figure 5a). Areas ifj1 and ifj2 may represent the receptorarchitectonic correlates of the functionally identified inferior frontal junction region, which has been reported to be involved in task switching [63–65] but also color and motion attention [66]. Area 44d differs from ifj1 by higher glutamate AMPA, acetylcholine muscarinic M₂, and GABA_A receptor densities, while area 45p shows higher kainate and M₂ receptor densities than dorsally adjacent ifs1 [46**,62]. In a functional imaging study of Makuuchi *et al.* [67] on verbal working memory, three activation

Figure 5

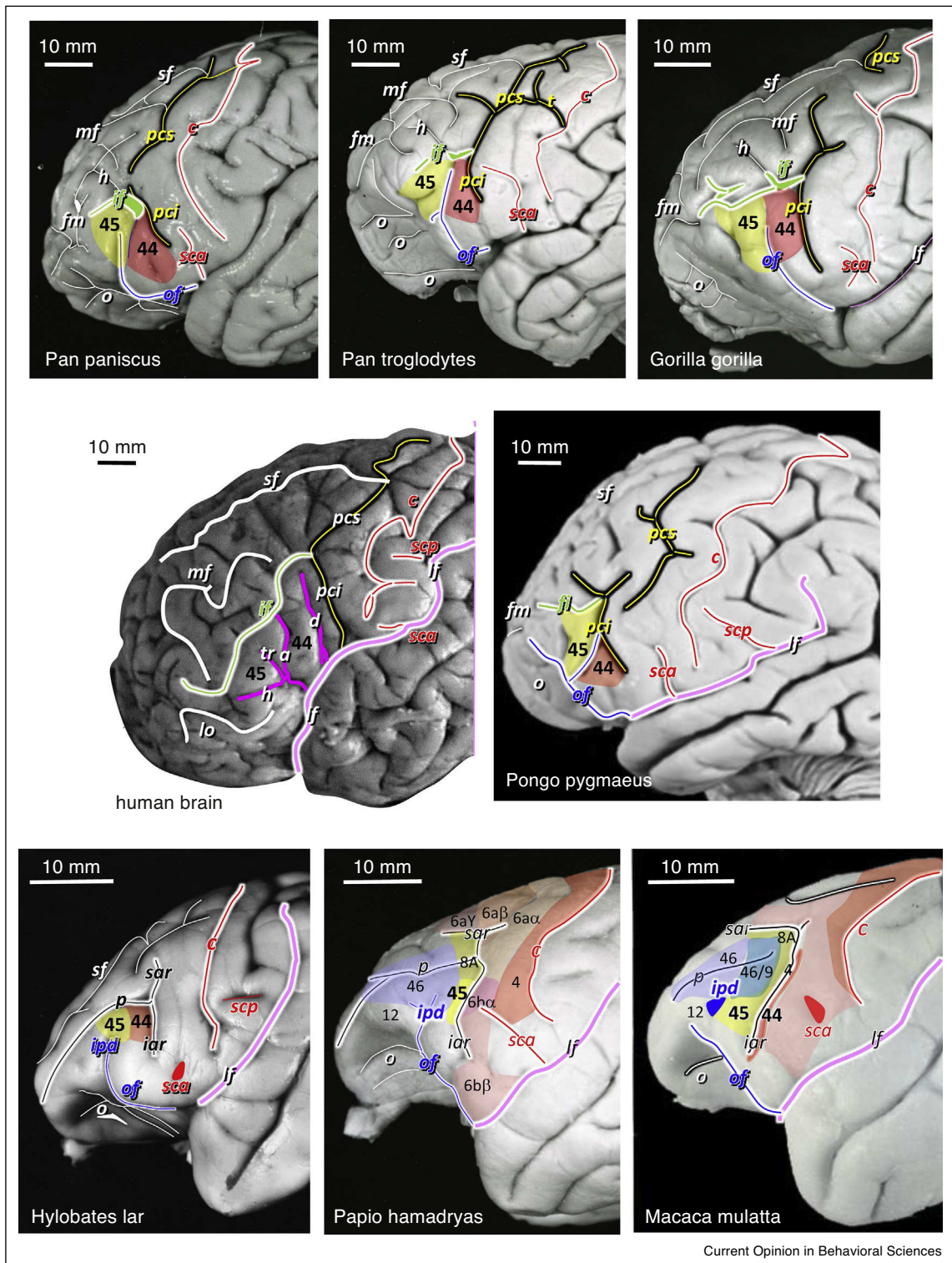


(a) Schematic map of the position of cytoarchitecturally and receptorarchitecturally defined areas of Broca's and surrounding regions in a human brain. **(b)** Maximum probability map of BA44 (red) and BA45 (yellow). The inset shows the probability map of BA45 with red colors indicating low variability, and blue colors corresponding to high variability. This probability map is based on the analysis of ten human postmortem brains [26**]. 6 premotor cortex, 4 primary motor cortex, 1 and 2 somatosensory areas. a ascending branch of the lateral fissure, c central sulcus, d diagonal sulcus, h horizontal branch of the lateral fissure, if inferior frontal sulcus, ip intraparietal sulcus, l lateral fissure, poc postcentral sulcus, pci inferior part of the precentral sulcus, pcs superior part of the precentral sulcus, sf superior frontal sulcus.

clusters were found within the left ifs: an anterior (LIFSa), a middle (LIFS_m) and a posterior (LIFS_p) cluster. These findings support the existence of a rostro-caudal organization of areas within the ifs, which corresponds to a receptor study [62]. Thus, areas in the inferior frontal sulcus may contribute to Broca's region,

extending the classical view of only BA44 and 45. Ventral to area 44v, areas op8 and op9 were discovered on the frontal operculum [46**]. A role of the frontal operculum for language has been described for processing local transitions as compared to hierarchical dependencies [68]. Area op8 contains higher AMPA, GABA_B, M₂, α₁,

Figure 6



Comparison of sulcal patterns between human, bonobo (*Pan paniscus*), common chimpanzee (*Pan troglodytes*), gorilla (*Gorilla gorilla*) orangutan (*Pongo pygmaeus*), gibbon (*Hylobates lar*), and baboon (*Papio hamadryas*) brains in lateral views of the frontal lobe. a, ascending sulcus (violet); c, central sulcus (red); d, diagonal sulcus (violet); fm, frontomarginal sulcus; h, horizontal sulcus (violet); iar, inferior branch of the arcuate sulcus (black); if, inferior (green) frontal sulcus; ipd, infraprincipal dimple (blue); lf, lateral fissure (pink); lo, lateral orbital sulcus (white); mf, middle frontal sulcus (white); o, orbital sulci (white); of, orbitofrontal sulcus (blue); p, principal sulcus (black); pci, inferior part of the precentral sulcus (yellow); pcs, superior part of the precentral sulcus (yellow); sar, superior branch of the arcuate sulcus (black); sca, anterior subcentral sulcus (red); scp, superior branch of the arcuate sulcus (black).

α_2 and 5-HT_{1A}, but lower kainate and GABA_A receptor densities than 44v. Area op9 is located rostral to op8 and ventral to 45a. The latter area shows lower kainate, α_1 and 5-HT₂, but higher NMDA, GABA_B, M₂, and M₃ receptor densities than op9. Areas op8 and op9 are in close neighborhood to the insular areas, which have been related to motor aspects of speech [69].

Finally, areas 6v1, 6v2 and 6r1 were identified in the precentral sulcus posterior to dysgranular areas 44v and 44d, and anterior to the primary motor cortex, BA4 [46**]. 6r1 differs from the 6v1 and 6v2 by an extremely thin and discontinuous layer IV. Area 6r1 shows higher M₂ and α_1 receptor densities than BA6 [46**].

Interhemispheric differences

Lateralization is a central question to any study on Broca's region [70], and structural asymmetries were interpreted as putative correlates of functional lateralization and dominance for language [5,71*]. Volumes of left BA44 show a consistent left-larger-than-right interhemispheric difference [26**,72–74], while the difference did not reach significance in BA45. In addition to volume, cytoarchitectonic features (e.g. volume fraction of cell bodies in different layers) differ between left and right BA44 and BA45. The somata of the largest layer III pyramidal neurons of left BA45 were significantly larger [75,76] and had a larger dendritic length [75] than those of the right BA45. The total number of neurons was significantly higher in left BA44 of the five male brains, and higher — although not significantly — in left BA45 of the five female brains [77].

The arcuate fascicle (for more details see next paragraph) showed a leftward lateralization in ~60% of human brains. Only ~20% of the brains had a symmetric arcuate fascicle, and the rest a mild leftward lateralization [78]. In contrast to its lower lateralization in female brains, 85% of the arcuate fascicles were left-lateralized in male brains. The prevalence of leftward asymmetry in the direct segment of the arcuate fascicle in right-handers is more pronounced than that of the Planum temporale, a region that was often selected as most prominent example for lateralization [79]. Considering the >90% left-hemispheric functional dominance of language in right handers, the asymmetry of the arcuate fascicle represents the most conspicuous structural sign of language lateralization.

Interhemispheric differences in the densities of transmitter receptors between ventral prefrontal (areas 44, 45, 47, op8, op9) and ventral motor and premotor areas (4, 6) were

mainly caused by the muscarinic M₂ receptors. Within the sample of analyzed areas, particularly BA44, but also BA45 and areas 6v1, and 6r1 differ between the hemispheres with higher receptor concentrations in left than in the right [46**].

Relationship of cortical areas to sulcal landmarks

The relation between BA44 and BA45 to surrounding sulci varies between brains and hemispheres [26**,42*], and is additive to intersubject variability in the sulcal pattern of this region [26**,42*]. For example, the border between both areas was coincident with the diagonal sulcus (d) in some hemispheres, or was completely absent (in about 50% of the hemispheres), or was found completely within BA44 [26**,42*]. The latter topographical relationship was the reason to suggest a subdivision of BA44 into two areas [23**]. The posterior border of BA44 to BA6 was found on the anterior, in other cases on the posterior wall of the pci. The position of this border varies between brains by a geodesic distance of 15–20 mm. Similar variation has been found in relation to superior and inferior walls of the if, but BA44 and BA45 never extended to the free surface of the medial frontal gyrus [26**], which makes this sulcus a good estimate for the dorsal extent of BA44 and 45. Apart from this, the macroscopic landmarks around and within Broca's region are not precise indicators of the borders between BA44 and BA45. Their intersubject variability is considerable [8,80,81], which is of growing importance for brain mapping, since modern MR scanners allow a spatial resolution below 1 mm.

Interindividual variability and probabilistic mapping

Probability maps of cytoarchitectonically defined cortical areas are a tool to localize *in vivo* functional neuroimaging data with respect to the underlying microstructural segregation (Figure 5). These maps represent interindividual variability in a common standard reference space [26**,42*], and inform on the probability with which a cytoarchitectonic areas can be found at an actual position. Such maps are accessible for the research community (e.g. <https://www.jubrain.fz-juelich.de/apps/cytoviewer/cytoviewer-main.php#>); they are also part of the human brain atlas of the European Human Brain Project (<https://www.humanbrainproject.eu/en/explore-the-brain/atlases/>) and other, publicly available sources, for example, the SPM Anatomy toolbox (http://www.fz-juelich.de/inm/inm-1/DE/Forschung/_docs/SPMANatomyToolbox/SPMANatomyToolbox_node.html), FSL (<https://fsl.fmrib.ox.ac.uk/fsl/fslwiki/Atlases>), or the scalable brain

(Figure 6 Legend Continued) posterior subcentral sulcus; sf, superior frontal sulcus (white); t, sulcus t; tr, triangular sulcus (violet). Approximate position of homologues of BA44 (red) and BA45 (yellow) in bonobo, common chimpanzee, gorilla, orangutan and gibbon from Schenker [85**], baboon from Watanabe-Saguchi [115] and rhesus from Morecraft *et al.* [116] brains.

atlas (https://scalablebrainatlas.incf.org/human/EAZ05_v20). Probabilistic maps have been used to localize activations during speech or language tasks.

In summary, clinical observations, functional neuroimaging data, and new, detailed architectonic maps suggest to extend the structural correlate of Broca's region to neighboring cortices, which are also involved in language and speech processing. Broca's region is much more complex than historical maps suggested. Combining cytoarchitectonic maps obtained in postmortem brains with data from neuroimaging studies helps to elucidate structural–functional correlations in the human brain. While such comparisons seem to be easy for fMRI data of large areas on the surface of the brain, structural–functional correlations are more difficult to establish for small areas within the sulci, including the frontal operculum/insula region. The close proximity of areas on opposite sides of a sulcus together with the low spatial resolution of most fMRI studies makes the analyses of structure–function relationships challenging. Different, mutually exclusive interpretations may result under such conditions, which imply different relationships of brain functions and cortical segregation: for example, a regional activation obtained in an fMRI study can be mapped to one single area, or involves different, neighboring areas, or relies on portions of two or more areas. It would be expected that high-field MR imaging in combination with improved functional paradigms will lead to a better understanding of language, and its anatomical correlates.

Evolution of Broca's region

The region ventral to the inferior frontal, dorsal to the lateral orbital, and anterior to the precentral sulcus contains cytoarchitectonic areas 44 and 45 of human Broca's region. This region is further subdivided by the ascending, diagonal, triangular and horizontal sulci (Figure 6). However, this sulcal pattern is highly variable [26**]. For example, the diagonal sulcus is the border between areas 44 and 45 in some human brains, in others the ascending ramus represents this border. If the triangular sulcus [5,9*,50**,82] is present between the ascending and horizontal sulci, it separates the more posterior area 45p from the rostral 45a (Figure 5; [46**]). In some human brains the diagonal sulcus cannot be found at all [26**]. Facing the variability in sulcal pattern of the human frontal lobe [82], it may be even more difficult to identify comparable sulci in the non-human primate brain [83], or to use the sulci as landmarks for localization of homologue cytoarchitectonic areas.

The inferior frontal and precentral sulci can easily be identified in the bonobo, common chimpanzee, gorilla and orangutan brains [83,84,85**,86–89]. Homologues of both sulci are not found in gibbon, baboon and macaque brains, which instead contain an arcuate and a principal

sulcus in the frontal lobe not seen in the human and great ape brains (Figure 6). An orbitofrontal sulcus is visible in all ape, baboon and macaque brains with the exception of the human brain (Figure 6). Thus, this sulcus represents a notable difference between ape and human brains, and is an important landmark for studies of endocasts in palaeoneurology.

Comparisons between sulci and the borders of the cytoarchitectonically defined areas 44 and 45 reveal that they do not precisely match in human [26**] or ape brains [85**,86–89]. However, similarities in cytoarchitecture, position in the inferior frontal lobe and shared non-language related functions (e.g. orofacial expressions, mirror neurons in the macaque premotor area F5 responding to communicative mouth gestures) have led to an identification of area 44 in various non-human primates [85**,86–94]. Notably, it has been proposed that simulation of motor acts as found in F5, caudally adjacent to area 44, may facilitate communication [95**]. Deep layer III and layer V of macaque area 44 contain very large or medium-sized pyramidal cells. Its layer IV is inconspicuous [94,96]. Therefore, area 44 of macaques can be classified as dysgranular cortex. Layer III of macaque area 45 is similar to that of area 44 by the occurrence of clusters of very large pyramidal cells in its deeper part. These pyramids are even larger than those in layer V. In contrast to area 44, area 45 has well-developed layer IV (granular cortex), and its layer V consists of a layer Va with medium-sized pyramidal cells and a cell-sparse layer Vb as a border region adjoining layer VI. Thus, the macaque map of Walker [97] must be revised, because he missed area 44, and the largest part of Petrides' area 45 [94] is occupied by the posterior half of Walker's area 46.

However, it is problematic to assume such homologies by comparing only the relatively distantly related macaques with humans. Instead we must perform additional studies of the cytoarchitecture and connections in our nearest relatives, that is, the bonobo and common chimpanzee and the other apes.

Species-specific, volitional calls and vocalizations of non-human primates require the ventral auditory pathway, which is also found in humans [98–103], and connects the superior and middle temporal gyri with cytoarchitectonic areas anterior and below area 44. These regions are putative homologues of human BA45 and BA47 in non-human primates [50**,93]. Thus, this and the more dorsally located and evolved arcuate fasciculus pathway [101,104,105], together with the cortical areas as sources and targets of this pathway may have undergone further differentiation for the processing of verbal information in humans. Accordingly, the wider spaced minicolumns of human BA44 and BA45 compared to areas 44 and 45 in non-human primates [106**] indicates the availability of more space for neural connections. A leftward asymmetry

and expanded connections with the middle and inferior temporal gyri compared to the great apes are further indicators of this differentiation.

In summary, the Broca region of non-human primates seems to have cortical areas with largely similar cytoarchitecture and connections comparable to those in the human language system. But how could humans develop a complex language on the basis of neuroanatomical conditions principally not different from those of non-human primates? The mechanism could be neural reuse specified as the ‘massive redeployment’ hypothesis by Anderson [107,108**] for evolutionary processes, or as the ‘recycling theory’ by Dehaene [109**] for developmental processes. Since the cultural environment is one important factor for functional differentiation and evolutionary history of the human brain, the development of language, reading and writing may be enabled by epigenetic/plasticity processes. These processes are driven by the specific cultural challenges without the genetically based re-programming for which the time span of cultural evolution is too short. This was conceptualized as ‘cultural neural reuse’ [110**], and may explain the phenotypic modifications of cortical areas in the human inferior frontal gyrus during brain evolution and individual development. Cultural neural reuse may lead to plastic reactions in the functionally less specialized areas in the inferior frontal gyrus of non-human primates. This epigenetic differentiation was interpreted as an extended case of epigenesis as proposed by D’Ambrosio and Colagè [110**].

References and recommended reading

Papers of particular interest, published within the period of review, have been highlighted as:

- of special interest
- of outstanding interest

Conflict of interest statement

Nothing declared.

Acknowledgement

This project has received funding from the European Union’s Horizon 2020 Research and Innovation Programme under Grant Agreement No 720270 (Human Brain Project SGA1).

References

1. Broca P: **Perte de la parole, ramollissement chronique et destruction partielle du lobe antérieur du cerveau.** *Bull Soc Anthropol Paris* 1861, **2**: 235–238, 301–321.
 2. Broca P: **Remarques sur le siège de la faculté du langage articulé, suivies d’une observation d’aphémie (perte de la parole).** *Bull Soc Anat* 1861, **6**:330–357.
 3. Broca P: **Sur le siege de la faculte du langage articule.** *Bull Soc Anthropol Paris* 1865, **6**:337–393.
 4. Dronkers NF, Plaisant O, Iba-Zizen MT, Cabanis EA: **Paul Broca’s historic cases: high resolution MR imaging of the brains of Leborgne and Lelong.** *Brain* 2007, **130**:1432–1441.
 5. Keller SS, Crow T, Foundas A, Amunts K, Roberts N: **Broca’s area: nomenclature, anatomy, typology and asymmetry.** *Brain Lang* 2009, **109**:29–48.
 6. Tremblay P, Dick AS: **Broca and Wernicke are dead, or moving past the classic model of language neurobiology.** *Brain Lang* 2016, **162**:60–71.
- Stimulating discussion on the concept of Broca’s area.
7. Brodmann K: *Vergleichende Lokalisationslehre der Großhirnrinde in ihren Prinzipien dargestellt auf Grund des Zellbaues.* Leipzig: Barth; 1909.
- Classical cytoarchitectonic map of cortical areas including Broca’s region.
8. Ono M, Kubik S, Abernathy CD: *Atlas of the Cerebral Sulci.* Stuttgart, New York: Thieme Verlag; 1990.
 9. Keller SS, Highley JR, Garcia-Finana M, Sluming V, Rezaie R, Roberts N: **Sulcal variability, stereological measurement and asymmetry of Broca’s area on MR images.** *J Anat* 2007, **211**:534–555.
- Comprehensive analysis of sulcal variability in Broca’s region.
10. Kononowa EP: **Structural variability of the cortex cerebri. Inferior frontal gyrus in adults.** In *Annals of the Brain Research Institute.* Edited by Sarkissov SA, Filimonoff IN. Moscow-Leningrad: State Press for Biological and Medical Literature; 1935: 49–118. (in Russian).
 11. Kononowa EP: **Variability in the structure of the human cerebral cortex. Frontal lobe of adult man.** In *Annals of the Brain Research Institute.* Edited by Sarkissov SA, Filimonoff IN. Moscow-Leningrad: State Press for Biological and Medical Literature; 1938:213–274. (in Russian).
 12. Harasty J, Halliday GM, Kril JJ: **Reproducible sampling regimen for specific cortical regions: application to speech-associated areas.** *J Neurosci Methods* 1996, **67**:43–51.
 13. McDermott KB, Petersen SE, Watson JM, Ojemann JG: **A procedure for identifying regions preferentially activated by attention to semantic and phonological relations using functional magnetic resonance imaging.** *Neuropsychologia* 2003, **41**:293–303.
 14. Wildgruber D, Riecker A, Hertrich I, Erb M, Grodd W, Ethofer T, Ackermann H: **Identification of emotional intonation evaluated by fMRI.** *Neuroimage* 2005, **24**:1233–1241.
 15. Demb JB, Desmond JE, Wagner AD, Vaidya CJ, Glover GH, Gabrieli JD: **Semantic encoding and retrieval in the left inferior prefrontal cortex: a functional MRI study of task difficulty and process specificity.** *J Neurosci* 1995, **15**:5870–5878.
 16. Desmond JE, Sum JM, Wagner AD, Demb JB, Shear PK, Glover GH, Gabrieli JD, Morrell MJ: **Functional MRI measurement of language lateralization in Wada-tested patients.** *Brain* 1995, **118**(Pt 6):1411–1419.
 17. Cutting LE, Clements AM, Courtney S, Rimrodt SL, Schafer JG, Bisesi J, Pekar JJ, Pugh KR: **Differential components of sentence comprehension: beyond single word reading and memory.** *Neuroimage* 2006, **29**:429–438.
 18. Sahin NT, Pinker S, Halgren E: **Abstract grammatical processing of nouns and verbs in Broca’s area: evidence from fMRI.** *Cortex* 2006, **42**:540–562.
 19. Samara Z, Evers EA, Goulas A, Uylings HB, Rajkowska G, Ramaekers JG, Stiers P: **Human orbital and anterior medial prefrontal cortex: intrinsic connectivity parcellation and functional organization.** *Brain Struct Funct* 2017.
 20. Uylings HB, Sanz-Arigita EJ, de VK, Pool CW, Evers P, Rajkowska G: **3-D cytoarchitectonic parcellation of human orbitofrontal cortex correlation with postmortem MRI.** *Psychiatry Res* 2010, **183**:1–20.
 21. Öngür D, Ferry AT, Price JL: **Architectonic subdivision of the human orbital and medial prefrontal cortex.** *J Comp Neurol* 2003, **460**:425–449.
 22. Sarkissov SA, Filimonoff IN, Kononowa EP, Preobrachenskaja IS: *Atlas of the Cytoarchitectonics of the Human Cerebral Cortex.* Moscow: Medgiz; 1955.

23. von Economo C, Koskinas GN: *Die Cytoarchitektur der Hirnrinde des erwachsenen Menschen*. Wien, Berl: Springer; 1925.
Most detailed historical description of the cytoarchitecture of core areas in Broca's region.
24. Zilles K, Palomero-Gallagher N, Bludau S, Mohlberg H, Amunts K: **Cytoarchitecture and maps of the human cerebral cortex**. In *Brain Mapping: An Encyclopedic Reference*. Edited by Toga AW. Elsevier; 2015:115-135.
25. Dapretto M, Bookheimer SY: **Form and content: dissociating syntax and semantics in sentence comprehension**. *Neuron* 1999, **24**:427-432.
26. Amunts K, Schleicher A, Bürgel U, Mohlberg H, Uylings HBM, Zilles K: **Broca's region revisited: cytoarchitecture and intersubject variability**. *J Comp Neurol* 1999, **412**:319-341.
First publication of an observer independent and statistically testable cytoarchitectonic parcellation of cortical areas in Broca's region including information on intersubject variability and interhemispheric differences.
27. Vogt O: **Die myeloarchitektonische Felerdung des menschlichen Stirnhirns**. *J Psychol Neurol* 1910, **15**:221-232.
Classical myeloarchitectonic map of areas in Broca's region.
28. Riegele L: **Die Cytoarchitektur der Felder der Brocaschen Regionen**. *J Physiol Neurol* 1931, **42**:496-514.
29. Ngowiyang G: *Die Zytoarchitektur des menschlichen Stirnhirns*. Academia Sinica, The National Research Institute of Psychology; 1934.
30. Kreht H: **Cytoarchitektur und motorisches Sprachzentrum**. *Z Mikrosk Anat Forsch* 1935, **39**:331-354.
31. Strasburger EH: **Vergleichende myeloarchitektonische Studien an der erweiterten Brocaschen Region des Menschen**. *J Psychol Neurol* 1938, **47** 461, 565.
32. Hopf A: **Über die Verteilung myeloarchitektonischer Merkmale in der Stirnhirnrinde beim Menschen**. *J Hirnforsch* 1956, **2**:311-333.
33. Burton MW, Small SL, Blumstein SE: **The role of segmentation in phonological processing: an fMRI investigation**. *J Cogn Neurosci* 2000, **12**:679-690.
34. Friederici AD, Alter K: **Lateralization of auditory language functions: a dynamic dual pathway model**. *Brain Lang* 2004, **89**:267-276.
35. Makuuchi M, Grodzinsky Y, Amunts K, Santi A, Friederici AD: **Processing noncanonical sentences in broca's region: reflections of movement distance and type**. *Cereb Cortex* 2013, **23**:694-702.
36. Indefrey P, Hellwig F, Herzog H, Seitz RJ, Hagoort P: **Neural responses to the production and comprehension of syntax in identical utterances**. *Brain Lang* 2004, **89**:312-319.
37. Heim S, Opitz B, Friederici AD: **Distributed cortical networks for syntax processing: Broca's area as the common denominator**. *Brain Lang* 2003, **85**:402-408.
38. Fiebach CJ, Schlesewsky M, Friederici AD: **Separating syntactic memory costs and syntactic integration costs during parsing: the processing of German WH-questions**. *J Mem Lang* 2002, **47**:250-272.
39. Hsieh L, Gandour J, Wong D, Hutchins GD: **Functional heterogeneity of inferior frontal gyrus is shaped by linguistic experience**. *Brain Lang* 2001, **76**:227-252.
40. Meyer M, Alter K, Friederici AD, Lohmann G, von Cramon DY: **fMRI reveals brain regions mediating slow prosodic modulations in spoken sentences**. *Hum Brain Mapp* 2002, **17**:73-88.
41. Horwitz B, Amunts K, Bhattacharyya R, Patkin D, Jeffries K, Zilles K, Braun AR: **Activation of Broca's area during the production of spoken and signed language: a combined cytoarchitectonic mapping and PET analysis**. *Neuropsychologia* 2003, **41**:1868-1876.
42. Amunts K, Weiss PH, Mohlberg H, Pieperhoff P, Eickhoff SB, Gurd JM, Marshall JC, Shah NJ, Fink GR, Zilles K: **Analysis of neural mechanisms underlying verbal fluency in cytoarchitectonically defined stereotaxic space — the roles of Brodmann areas 44 and 45**. *Neuroimage* 2004, **22**:42-56.
Functional neuroimaging study combined with cytoarchitectonic probabilistic maps of areas 44 and 45 in standard reference space. Such comparison enables reliable structural/functional correlations.
43. Friederici AD, Kotz SA: **The brain basis of syntactic processes: functional imaging and lesion studies**. *Neuroimage* 2003, **20** (Suppl. 1):S8-S17.
44. Ardila A, Bernal B, Rosselli M: **How localized are language brain areas? A review of brodmann areas involvement in oral language**. *Arch Clin Neuropsychol* 2016, **31**:112-122.
A recent critical review of structural/functional relations in Broca's region.
45. Hagoort P: **Nodes and networks in the neural architecture for language: Broca's region and beyond**. *Curr Opin Neurobiol* 2014, **28**:136-141.
A recent review of structural/functional concepts of language-related brain regions.
46. Amunts K, Lenzen M, Friederici AD, Schleicher A, Morosan P, Palomero-Gallagher N, Zilles K: **Broca's region: novel organizational principles and multiple receptor mapping**. *PLoS Biol* 2010, **8** <http://dx.doi.org/10.1371/journal.pbio.1000489>.
Introduction of multiple new cytoarchitectonically and receptorarchitectonically defined cortical areas in Broca's region and surrounding cortex.
47. Amunts K, Zilles K: **Architecture and organizational principles of Broca's region**. *Trends Cogn Sci* 2012, **16**:418-426.
Recent review of anatomical concepts including microscopical and recepto architectural findings.
48. Foundas AL, Eure KF, Luevano LF, Weinberger DR: **MRI asymmetries of Broca's area: the pars triangularis and pars opercularis**. *Brain Lang* 1998, **64**:282-296.
49. Foundas AL, Weisberg A, Browning CA, Weinberger DR: **Morphology of the frontal operculum: a volumetric magnetic resonance imaging study of the pars triangularis**. *J Neuroimaging* 2001, **11**:153-159.
50. Petrides M: *Neuroanatomy of Language Regions of the Human Brain*. Amsterdam: Elsevier; 2013.
Comprehensive review of the neuroanatomy of Broca's region including comparative aspects in the brains of non-human primates.
51. Foerster O: **The cerebral cortex in man**. *Lancet* 1931, **218**:309-312.
52. Vogt C, Vogt O: **Allgemeinere Ergebnisse unserer Hirnforschung**. *J Psychol Neurol* 1919, **25**:279-462.
53. Duffau H, Capelle L, Denvil D, Gatignol P, Sichez N, Lopes M, Sichez JP, Van ER: **The role of dominant premotor cortex in language: a study using intraoperative functional mapping in awake patients**. *Neuroimage* 2003, **20**:1903-1914.
54. Ojemann G, Ojemann J, Lettich E, Berger M: **Cortical language localization in left, dominant hemisphere. An electrical stimulation mapping investigation in 117 patients**. *J Neurosurg* 1989, **71**:316-326.
55. Hagoort P: **On Broca, brain, and binding: a new framework**. *Trends Cogn Sci* 2005, **9**:416-423.
56. Willems RM, Hagoort P, Casasanto D: **Body-specific representations of action verbs: neural evidence from right- and left-handers**. *Psychol Sci* 2010, **21**:67-74.
57. Buccino G, Colage I, Gobbi N, Bonaccorso G: **Grounding meaning in experience: a broad perspective on embodied language**. *Neurosci Biobehav Rev* 2016, **69**:69-78.
Detailed study of the embodiment concept of language.
58. Buccino G, Marino BF, Bulgarelli C, Mezzadri M: **Fluent speakers of a second language process graspable nouns expressed in L2 like in their native language**. *Front Psychol* 2017, **8**:1306.
59. Palomero-Gallagher N, Amunts K, Zilles K: **Transmitter receptor distribution in the human brain**. In *Brain Mapping: An Encyclopedic Reference*. Edited by Toga AW. San Diego: Academic Press/Elsevier; 2015:261-275.

Description on the biological meaning of receptor architecture for concepts of brain organization including a comprehensive description of the fingerprinting method.

60. Zilles K, Palomero-Gallagher N: **Comparative analysis of receptor types that identify primary cortical sensory areas**. In *Evolution of Nervous Systems*, edn 2. Edited by Kaas JH. Oxford: Elsevier; 2017:225-245.
61. Zilles K, Bacha-Trams M, Palomero-Gallagher N, Amunts K, Friederici AD: **Common molecular basis of the sentence comprehension network revealed by neurotransmitter receptor fingerprints**. *Cortex* 2015, **63**:79-89.
- Comprehensive analysis of the receptor-based identification of language-related areas relevant for sentence comprehension.
62. Bradler S, Palomero-Gallagher N, Schleicher A, Zilles K, Amunts K: **Receptorarchitectonic mapping of four new areas in the inferior frontal sulcus of the human brain**. *18th Annual Meeting of the Organization for Human Brain Mapping; Beijing, 10th-14th June: 2012*.
63. Amunts K, von Cramon DY: **The anatomical segregation of the frontal cortex: what does it mean for function?** *Cortex* 2006, **42**:525-528.
64. Derrfuss J, Brass M, von Cramon DY: **Cognitive control in the posterior frontolateral cortex: evidence from common activations in task coordination, interference control, and working memory**. *Neuroimage* 2004, **23**:604-612.
65. Derrfuss J, Brass M, von Cramon DY, Lohmann G, Amunts K: **Neural activations at the junction of the inferior frontal sulcus and the inferior precentral sulcus: interindividual variability, reliability, and association with sulcal morphology**. *Hum Brain Mapp* 2009, **30**:299-311.
66. Zanto TP, Rubens MT, Bollinger J, Gazzaley A: **Top-down modulation of visual feature processing: the role of the inferior frontal junction**. *Neuroimage* 2010, **53**:736-745.
67. Makuuchi M, Bahlmann J, Anwender A, Friederici AD: **Segregating the core computational faculty of human language from working memory**. *Proc Natl Acad Sci U S A* 2009, **106**:8362-8367.
68. Friederici AD, Bahlmann J, Heim S, Schubotz RI, Anwender A: **The brain differentiates human and non-human grammars: functional localization and structural connectivity**. *Proc Natl Acad Sci U S A* 2006, **103**:2458-2463.
69. Mandelli ML, Vitali P, Santos M, Henry M, Gola K, Rosenberg L, Dronkers N, Miller B, Seeley WW, Gorno-Tempini ML: **Two insular regions are differentially involved in behavioral variant FTD and nonfluent/agrammatic variant PPA**. *Cortex* 2016, **74**:149-157.
70. Foundas AL, Leonard CM, Gilmore RL, Fennell EB, Heilman KM: **Pars triangularis asymmetry and language dominance**. *Proc Natl Acad Sci U S A* 1996, **93**:719-722.
71. Amunts K: **Structural indices of asymmetry**. In *The Two Halves of the Brain*. Edited by Hugdahl K, Westerhausen R. Cambridge: MIT Press; 2010:145-175.
- Comprehensive review of the relation between landmarks and cytoarchitecture in Broca's region.
72. Amunts K, Zilles K: **Advances in cytoarchitectonic mapping of the human cerebral cortex**. *Anatom Basis Funct Magn Reson Imaging* 2001, **11**:151-169.
73. Amunts K, Zilles K: **A multimodal analysis of structure and function in Broca's region**. In *Broca's Region*. Edited by Gieddinsky Y, Amunts K. New York: Oxford University Press; 2006:67-82.
74. Galaburda AM: **La région de Broca: Observations anatomiques faites un siècle après la mort de son découvreur**. *Rev Neurol (Paris)* 1980, **136**:609-616.
75. Hayes TL, Lewis DA: **Magnopyramidal neurons in the anterior motor speech region. Dendritic features and interhemispheric comparisons**. *Arch Neurol* 1996, **53**:1277-1283.
76. Hayes TL, Lewis DA: **Anatomical specialization of the anterior motor speech area: hemispheric differences in magnopyramidal neurons**. *Brain Lang* 1995, **49**:289-308.
77. Uylings HB, Jacobsen AM, Zilles K, Amunts K: **Left-right asymmetry in volume and number of neurons in adult Broca's area**. *Cortex* 2006, **42**:652-658.
78. Catani M, Allin MP, Husain M, Pugliese L, Mesulam MM, Murray RM, Jones DK: **Symmetries in human brain language pathways correlate with verbal recall**. *Proc Natl Acad Sci U S A* 2007, **104**:17163-17168.
79. Geschwind N, Levitsky W: **Human brain: left-right asymmetries in temporal speech region**. *Science* 1968, **161**:186-187.
80. Tomaiuolo F, MacDonald JD, Caramanos Z, Posner G, Chiavaras M, Evans AC, Petrides M: **Morphology, morphometry and probability mapping of the pars opercularis of the inferior frontal gyrus: an in vivo MRI analysis**. *Eur J Neurosci* 1999, **11**:3033-3046.
81. Duvernoy H: *The Human Brain*. Wien: Springer; 1991.
82. Eberstaller O: *Das Stirnhirn. Ein Beitrag zur Anatomie der Oberfläche des Grosshirns*. Wien: Urban & Schwarzenberg; 1890.
83. Mingazzini G: **Beitrag zur Morphologie der äußeren Grosshirnhemisphärenoberfläche bei den Anthropoiden (Schimpanse und Orang)**. *Arch Psychiat* 1928, **85**:1-219.
84. Cantalupo C, Hopkins WD: **Asymmetric Broca's area in great apes**. *Nature* 2001, **414**:505.
85. Schenker NM: *Comparative analysis of Broca's area in hominoids*. (PhD Thesis UC) 2007. San Diego. <https://escholarship.org/uc/item/7br1r08t>.
- Comprehensive macroscopic and microscopic analysis of Broca's area in hominoids
86. Schenker NM, Buxhoeveden DP, Blackmon WL, Amunts K, Zilles K, Semendeferi K: **A comparative quantitative analysis of cytoarchitecture and minicolumnar organization in Broca's area in humans and great apes**. *J Comp Neurol* 2008, **510**:117-128.
87. Schenker NM, Hopkins WD, Spocter MA, Garrison A, Stimpson CD, Erwin JM, Hof PR, Sherwood CC: **Broca area homologue in chimpanzees (*Pan troglodytes*): probabilistic mapping, asymmetry and comparison to humans**. *Cereb Cortex* 2010, **20**:730-742.
88. Semendeferi K: **The frontal lobes of the great apes with a focus on the gorilla and the orangutan**. In *The Mentality of Gorillas and Orangutans: Comparative Perspectives*. Edited by Parker ST, Mitchell RW, Miles HL. Cambridge: Cambridge University Press; 2004:70-98.
89. Sherwood CC, Broadfield DC, Holloway RL, Gannon PJ, Hof PR: **Variability of Broca's area homologue in African great apes: implications for language evolution**. *Anat Rec* 2003, **271A**:276-285.
90. Galaburda AM, Pandya DN: **Role of architectonica and connections in the study of primate brain evolution**. In *Primate Brain Evolution: Methods and Concepts*. Edited by Falk D, Armstrong E. New York: Plenum; 1982:203-216.
91. Rizzolatti G, Arbib MA: **Language within our grasp**. *Trends Neurosci* 1998, **21**:188-194.
92. Preuss TM: **Taking the measure of diversity: comparative alternatives to the model-animal paradigm in cortical neuroscience**. *Brain Behav Evol* 2000, **55**:287-299.
93. Rilling JK, Glasser MF, Jbabdi S, Andersson J, Preuss TM: **Continuity, divergence, and the evolution of brain language pathways**. *Front Evol Neurosci* 2012, **3**:11.
94. Petrides M, Cadoret G, Mackey S: **Orofacial somatomotor responses in the macaque monkey homologue of Broca's area**. *Nature* 2005, **435**:1235-1238.
95. Rizzolatti G, Fogassi L, Gallese V: **Neurophysiological mechanisms underlying the understanding and imitation of action**. *Nat Rev Neurosci* 2001, **2**:661-670.
- Fundamental review on understanding and imitation on which many hypotheses on language evolution have been built.

96. Petrides M, Pandya DN: **Dorsolateral prefrontal cortex: comparative cytoarchitectonic analysis in the human and the macaque brain and corticocortical connection patterns.** *Eur J Neurosci* 1999, **11**:1011-1036.
97. Walker AE: **A cytoarchitectural study of the prefrontal area of the macaque monkey.** *J Comp Neurol* 1940, **73**:59-86.
98. Frey S, Campbell JS, Pike GB, Petrides M: **Dissociating the human language pathways with high angular resolution diffusion fiber tractography.** *J Neurosci* 2008, **28**:11435-21144.
99. Frey S, Mackey S, Petrides M: **Cortico-cortical connections of areas 44 and 45B in the macaque monkey.** *Brain Lang* 2014, **131**:36-55.
100. Makris N, Pandya DN: **The extreme capsule in humans and rethinking of the language circuitry.** *Brain Struct Funct* 2009, **213**:343-358.
101. Aboitiz F: **Gestures, vocalizations, and memory in language origins.** *Front Evol Neurosci* 2012, **4**:2.
102. Hage SR, Nieder A: **Single neurons in monkey prefrontal cortex encode volitional initiation of vocalizations.** *Nat Commun* 2013, **4**:2409.
103. Thiebaut de Schotten M, Dell'Acqua F, Valabregue R, Catani M: **Monkey to human comparative anatomy of the frontal lobe association tracts.** *Cortex* 2012, **48**:81-95.
104. Rilling JK, Glasser MF, Preuss TM, Ma X, Zhao T, Hu X, Behrens TE: **The evolution of the arcuate fasciculus revealed with comparative DTI.** *Nat Neurosci* 2008, **11**:426-428.
105. Kelly C, Uddin LQ, Shehzad Z, Margulies DS, Castellanos FX, Milham MP, Petrides M: **Broca's region: linking human brain functional connectivity data and non-human primate tracing anatomy studies.** *Europ J Neurosci* 2010, **32**:383-398.
106. Rilling JK: **Comparative primate neurobiology and the evolution of brain language systems.** *Curr Opin Neurobiol* 2014, **28**:10-14.
Comprehensive presentation of the structural communalities of the language system in humans and non-human primates.
107. Anderson ML: **The massive redeployment hypothesis and the functional topography of the brain.** *Philos Psychol* 2007, **21**:143-174.
108. Anderson ML: **Neural reuse: a fundamental organizational principle of the brain.** *Behav Brain Sci* 2010, **33**:4.
General analysis of the neural reuse theory and its implications. This article also contains interesting commentaries by various authors added at the end of the Anderson paper.
109. Dehaene S, Cohen L: **Cultural recycling of cortical maps.** *Neuron* 2007, **56**:384-398.
Hypothesis how cultural inventions can invade evolutionarily older brain circuits and inherit many of their structural constraints. Examples by experimental findings on representations of letter strings and numbers, which are consistently found in cortical maps.
110. D'Ambrosio P, Colagè I: **Extending epigenesis: from phenotypic plasticity to the bio-cultural feedback.** *Biol Philos* 2017, **32**:705-728.
The concept of 'cultural neural reuse' as a hypothesis focused on the relationship between cultural evolution and epigenesis.
111. Palomero-Gallagher N, Zilles K: **Cortical layers: cyto-, myelo-, receptor- and synaptic architecture in human cortical areas.** *Neuroimage* 2017 <http://dx.doi.org/10.1016/j.neuroimage.2017.08.035>. (Epub ahead of print).
Detailed analysis of multiple transmitter receptors and their impact on concepts of cortical layering in 44 cyto- and receptor architectonically identified cortical areas including Broca's region
112. Caspers S, Schleicher A, Bacha-Trams M, Palomero-Gallagher N, Amunts K, Zilles K: **Organization of the human inferior parietal lobule based on receptor architectonics.** *Cereb Cortex* 2013:85-628.
113. Palomero-Gallagher N, Zilles K: **Cyto- and receptorarchitectonic mapping of the human brain.** In *Brain Banking Neurological and Psychiatric Disorders*. Edited by Huitinga I, Webster M. Amsterdam: Elsevier; 2017. (in press).
114. Caspers J, Palomero-Gallagher N, Caspers S, Schleicher A, Amunts K, Zilles K: **Receptor architecture of visual areas in the face and word-form recognition region of the posterior fusiform gyrus.** *Brain Struct Funct* 2015, **220**:205-219.
115. Watanabe-Sawaguchi K, Kubota K, Arikuni T: **Cytoarchitecture and intrafrontal connections of the frontal cortex of the brain of the hamadryas baboon (*Papio hamadryas*).** *J Comp Neurol* 1991, **311**:108-133.
116. Morecraft RJ, Stilwell-Morecraft KS, Ge J, Cipolloni PB, Pandya DN: **Cytoarchitecture and cortical connections of the anterior insula and adjacent frontal motor fields in the rhesus monkey.** *Brain Res Bull* 2015, **119**:52-72.