NeuroImage: Clinical 25 (2020) 102114

Contents lists available at ScienceDirect

NeuroImage: Clinical

journal homepage: www.elsevier.com/locate/ynicl

Electroconvulsive therapy modulates grey matter increase in a hub of an affect processing network

Julia A. Camilleri[a,b,1], Felix Hoffstaedter[a,b,1], Maxim Zavorotny[c], Rebecca Zöllner[c], Robert Christian Wolf[d,e], Philipp Thomann[d], Ronny Redlich[f], Nils Opel[f], Udo Dannlowski[f], Michael Groezinger[g], Traute Demirakca[h], Alexander Sartorius[h], Simon B. Eickhoff[a,b], Thomas Nickl-Jockschat[g,i,j,*]

[a] Institute of Neuroscience and Medicine-7, Juelich Research Center, Juelich, Germany
[b] Institute of Systems Neuroscience, Heinrich Heine University, Duesseldorf, Germany
[c] Department of Psychiatry and Psychotherapy, Marburg Center for Mind, Brain and Behavior – MCMBB, Philipps-University Marburg, 35043 Marburg, Germany
[d] Center for Psychosocial Medicine, Department of General Psychiatry, Heidelberg University, Heidelberg, Germany
[e] Center for Mental Health, Odenwald District Healthcare Center, Erbach, Germany
[f] Department of Psychiatry and Psychotherapy, University of Muenster, Muenster, Germany
[g] Department of Psychiatry, Psychotherapy and Psychosomatics, RWTH Aachen University, Aachen, Germany
[h] Central Institute of Mental Health, Mannheim, Germany
[i] Department of Psychiatry, Carver College of Medicine, University of Iowa, Iowa City, USA
[j] Iowa Neuroscience Institute, University of Iowa, Iowa City, USA

ARTICLE INFO

Keywords:
Electroconvulsive therapy
Brain structure
Morphometry
Connectivity
Emotion
Memory

ABSTRACT

A growing number of recent studies has suggested that the neuroplastic effects of electroconvulsive therapy (ECT) might be prominent enough to be detected through changes of regional gray matter volumes (GMV) during the course of the treatment. Given that ECT patients are difficult to recruit for imaging studies, most publications, however, report only on small samples. Addressing this challenge, we here report results of a structural imaging study on ECT patients that pooled patients from five German sites.

Whole-brain voxel-based morphometry (VBM) analysis was performed to detect structural differences in 85 patients with unipolar depression before and after ECT, when compared to 86 healthy controls. Both task-independent and task-dependent physiological whole-brain functional connectivity patterns of these regions were modeled using additional data from healthy subjects. All emerging regions were additionally functionally characterized using the BrainMap database.

Our VBM analysis detected a significant increase of GMV in the right hippocampus/amygdala region in patients after ECT compared to healthy controls. In healthy subjects this region was found to be enrolled in a network associated with emotional processing and memory. A region in the left fusiform gyrus was additionally found to have higher GMV in controls when compared with patients at baseline. This region showed minor changes after ECT.

Our data points to a GMV increase in patients post ECT in regions that seem to constitute a hub of an emotion processing network. This appears as a plausible antidepressant mechanism and could explain the efficacy of ECT not only in the treatment of unipolar depression, but also of affective symptoms across heterogeneous disorders.

1. Introduction

Since its introduction to psychiatry 8 decades ago (Cerletti and Bini, 1938), electroconvulsive therapy (ECT) has proven to be a highly efficacious therapeutic approach within a broad syndromal spectrum (American Psychiatric Association, 2001), improving especially affective symptoms across disorders (Mukherjee et al., 1994; Chanpattana et al., 1999; Chanpattana and Chakrabhand, 2001; UK ECT Review Group, 2003). At least in Western industrialized countries, unipolar depression is the major domain of use

* Corresponding author at: Dep. of Psychiatry, Iowa Neuroscience Institute, University of Iowa, 162 Newton Road, Iowa City, IA, USA.
E-mail address: thomas-nickl-jockschat@uiowa.edu (T. Nickl-Jockschat).
[1] Both authors contributed equally.

https://doi.org/10.1016/j.nicl.2019.102114
Received 3 June 2019; Received in revised form 21 November 2019; Accepted 2 December 2019
Available online 09 December 2019
2213-1582/ © 2019 The Authors. Published by Elsevier Inc. This is an open access article under the CC BY-NC-ND license (http://creativecommons.org/licenses/BY-NC-ND/4.0/).

(Leiknes et al., 2012), a status that ECT largely has earned due to its superior antidepressant potential even in therapy-resistant major depression (UK ECT Review Group, 2003). In the last decade, the neurotrophic hypothesis has become the most favorite explanation approach for the mechanism of action. This comparatively broad model is based on the assumption that the clinical effects of ECT are mediated by the restoration of dysfunctional neural networks, e.g., due to increased neuroneogenesis, enhanced synaptogenesis or heightened axonal tropism (Kondratyev et al., 2002; Santarelly et al., 2003; Piccinni et al., 2009; Tang et al., 2012; Inta et al., 2013).

While most of the findings supporting this hypothesis are derived either from animal models (Malberg et al., 2000; Chen et al., 2009) or studies on neurotrophic markers in the peripheral blood of patients (Kondryatev et al., 2002; Minelli et al., 2011; Bumb et al., 2015), a growing number of recent studies have yielded evidence that the neuroplastic effects of ECT might be so pronounced that they can even be detected by structural magnetic resonance imaging (MRI). While various imaging modalities, such as, e.g., diffusion tensor imaging (DTI), have been applied (Lyden et al., 2014; Nickl-Jockschat et al., 2016), most of the publications have focused on changes of regional grey matter volumes during the course of ECT. Grey matter volume increases in the medial, but also the lateral temporal lobe, the anterior cingulate cortex and the insula, mainly lateralized to the right hemisphere, were amongst the most frequently reported findings (reviewed in Yrondi et al., 2018).

Two main factors, however, challenge the notion that grey matter increases are necessary to mediate the antidepressant effects of ECT. First, a majority of whole-brain VBM studies find significant differences in patients in the course of the treatment, but systematic comparisons of patients before and after ECT to healthy controls were not routinely conducted (Bouckaert et al., 2016) and sometimes failed to detect significant volume changes in the course of ECT (Qiu et al., 2016). While the seemingly paradox contrast of often highly significant longitudinal findings without any significant changes in the group contrasts can be explained by the latter being "noisier", it impedes a clear-cut biological interpretation of the imaging results. In other words: do volume increases due to ECT simply reflect a *restitutio ad integrum* of an endophenotype associated with major depression or are more complex mechanisms involved?

Second, the fact that the relation of neuroplastic processes to treatment response remains unclear in a broader sense challenges the notion that grey matter increases are necessary to mediate the antidepressant effects of ECT. Comparatively few publications report on correlations between grey matter volume changes and treatment response, but recent data challenges the notion that such a connection exists (Sartorius et al., 2016; Oltedal et al., 2018). Additionally, a recent study has found no correlation between gray matter volume increase and clinical finding improvement (Sartorius et al., 2019). Even more challenging seems the aspect that no grey matter changes were found in a sample that responded to ECT, thus, raising the question, whether grey matter changes were necessary at all to mediate the antidepressant effect (Nickl-Jockschat et al., 2016).

A considerable amount of this heterogeneity in findings might be attributable to relatively small sample sizes. Voxel-wise approaches with unrestricted brain-wide inference spaces are powerful tools for observer-independent data-driven analyses (Ashburner and Friston, 2005, 2011). However, adequate sample sizes are a key issue in these studies, because of the high number of multiple comparisons across the voxels of the entire brain. ECT, in turn, is administered only to a small number of patients, which are often amongst the most severely affected (Leiknes et al., 2012; Loh et al., 2013) and, therefore, often hard to recruit for imaging studies. Important to note here is that a recent study has published a mega-analysis of 281 ECT patients pooled from 10 different sites (Oltedal et al., 2018), which performed a region-of-interest (ROI) - based approach limited to the hippocampus. While such an approach has its advantages due to a greater sensitivity to pick up changes within a given brain region, it is unable to detect effects outside the ROI.

Given these difficulties to recruit large samples at a single site, pooling imaging data sets over several sites seem to be an adequate approach to address this crucial problem and provide the sample sizes needed for a robust detection of ECT-related neuroplastic processes. Addressing these challenges, we here present a multi-site study that pools over a large data set of 85 ECT patients with unipolar depression and 86 controls matched for gender and age. Utilizing this large data set, the study was motivated by two major aims. Firstly, the study was aimed at identifying regions that undergo structural changes in the course of ECT. To this aim we performed whole-brain VBM analyses to detect brain structural differences in (1) patients before and (2) after ECT compared to healthy controls, as well as (3) longitudinal changes in these patients. This involved three separate VBM analyses, including two separate cross-sectional and independent samples comparisons of the volumes of patient before ECT with healthy controls, and patients after ECT with healthy controls, in addition to a longitudinal within-subject comparison of patients before and after ECT. Additionally, since we regarded the identification of the physiological properties of the regions structurally altered by ECT as a necessary first step to better understand the pathophysiological changes in depression and its remission by ECT, a second aim for our study was to understand and characterize the physiological functions of these regions in healthy individuals. This was done using a data-driven approach, employing the information provided by the BrainMap database that pools over neuroimaging experiments in healthy subjects (Laird et al., 2009, 2011). Such an approach, which has been previously used in studies that have investigated multiple disorders including schizophrenia and depression (Goodkind et al., 2015) and psychopathy (Poeppl et al., 2019), avoids subjective interpretations, but relies upon an observer-independent method. Furthermore, since the physiological properties of a given brain region are largely influenced by its connectivity profile, we analysed data from healthy subjects to carry out task-based and task-independent connectivity analyses of the brain regions affected by ECT to delineate the connectivity profiles of these regions.

2. Methods and materials

2.1. Study design and participants

To obtain an adequate number of participants for robust statistics, a group of 85 patients with major depression that had undergone ECT treatment and 86 healthy controls were pooled over five different measurement sites (Aachen, Heidelberg, Mannheim, Marburg, Muenster) and matched for age and gender per site. Patients underwent magnetic resonance imaging (MRI) to acquire T1-weighted scans before start of ECT treatment and after completion of the ECT index series using identical protocols. Healthy controls were subjected to two T1-weighted MP-RAGE sequences within a time interval.

Patients were recruited based on a positive diagnosis of treatment-resistant unipolar depression according to either the International Classification of Diseases (ICD-10) criteria in the case of the Aachen and Marburg sites or the Diagnostic and Statistics Manual (DSM IV) in the cases of the Münster, Mannheim and Heidelberg sites. Exclusion criteria for the patient sample across all sites included severe psychiatric or neurological comorbididties, substance dependence, gravidity and the general exclusion criteria for MRI studies. Healthy subjects recruited for group comparisons did not have a history of neurological or psychiatric disorders and all subjects gave written informed consent to participate in the study as approved by the local ethics committees. Table 1 provides details of subject characteristics for each of the five sites. Table 2 summarizes the parameters for MRI acquisition.

Table 1
Overview over the demographic characteristics of the patient sample from the 5 sites. Sample sizes, mean age, sex ratios, mean number of ECT and Hamilton Depression Scale (HAMD) scores before and after ECT are reported for each of the sites separately and the pooled sample.

	Aachen	Heidelberg	Münster	Mannheim	Marburg	Pooled data
Patients						
Sample size	19	11	28	18	9	85
Mean age ± SD (years)	57.58 ± 10.08	45.73 ± 11.69	46.18 ± 10.23	53 ± 14.1	48 ± 13.56	50.31 ± 12.32
Sex (male/ female)	15/4	4/7	11/17	9/9	7/2	46/39
Mean no. of ECT sessions	10.95 ± 3.17	10.64 ± 2.77	14.07 ± 4.95	11.28 ± 4.79	11.78 ± 1.92	12.09 ± 4.24
Mean pre-ECT HAMD score	26.16 ± 4.63	16.64 ± 6.79	25.21 ± 5.36	31.78 ± 8.2	19.22 ± 6.91	26.36 ± 7.05
Mean post-ECT HAMD score	11.53 ± 6.24	6.64 ± 4.08	13.14 ± 7.88	10.56 ± 7.26	15.89 ± 7.29	11.68 ± 7.23
Remission rate		11				
Response rate		7				

2.2. ECT treatment

ECT treatment across all sites was performed with a Thymatron® IV device (Somatics, LLC. Lake Bluff, IL, USA). Treatment was generally started with right unilateral (RUL) electrode placement however, treatment was switched to bilateral ECT because of insufficient response to unilateral treatment. Additionally, it should be noted that other treatment parameters differed between sites, namely with regard to the determination of the seizure threshold and anesthesia. Table 3 gives an overview over the treatment parameters at each site.

2.3. Voxel-Based morphometry (VBM)

T1-weighted images were segmented using the Geodesic Shooting Algorithm (Ashburner and Friston, 2011) as implemented in the CAT12 toolbox (http://www.neuro.uni-jena.de/cat/) in SPM12. The scans of the patients before and after ECT were processed using the longitudinal segmentation in CAT12 (version r1184), which was specifically developed and optimized for detecting subtle effects over shorter time ranges. The images before and after ECT intervention were registered to their mean image for each subject using an inverse-consistent realignment. Spatial normalization was estimated for the mean only and applied to both images. Images of controls were individually normalized using the same algorithm and the modulated GM segments were smoothed with 8 mm FWHM. Differences across scanner sites including scanner parameters, were controlled for statistically by treating site as a confounding variable and removing any variance that is attributable to site prior to the group comparisons. The effect of ECT treatment (pre-ECT-Pat < > post-ECT-Pat) was assessed via a paired *t*-test including total intracranial volume as covariate. ANOVAs were computed for patients at baseline and controls (pre-ECT-Pat < > Con), and patients after ECT and controls (post-ECT-Pat < > Con). Results were assessed for statistical significance at a conservative threshold of $p < 0.001$, FWE-corrected for multiple comparisons.

2.3. Functional characterization

The regions that emerged from our group comparisons were then functionally characterized based on the meta-data from the BrainMap database (Fox et al., 2002; Laird et al., 2009, 2011), using both forward and reverse inference, as performed in previous studies (Nickl-Jockschat et al., 2015; Wensing et al., 2017). The key idea behind this approach is to identify all experiments that activate a particular region of interest and then analyze the experimental meta-data describing the experimental settings that were employed in these. This allows statistical inference on the type of tasks that evoke activation in a particular region. This data-driven approach, allows the study of brain-behavior relationships at the meta-analytical level and ensures that any subjective interpretation that could arise from individual studies is eliminated and presents results based on a large number of studies.

In this study, we used behavioral domains (BD) from the BrainMap database that describe the cognitive processes probed by an experiment. In the forward inference approach, the functional profile was determined by identifying taxonomic labels for which the probability of finding activation in the respective region/set of regions was significantly higher than the overall (*a priori*) chance across the entire database. That is, we tested whether the conditional probability of activation given a particular label [P(Activation|Task)] was higher than the baseline probability of activating the region(s) in question *per se* [P (Activation)]. Significance was established using a binomial test [$p < 0.05$, corrected for multiple comparisons using false discovery rate (FDR)]. In the reverse inference approach, the functional profile was

Table 2
Overview over the acquisition parameters and the time points of the scans used at each of the 5 sites. Reported are the time points for the first (= before the ECT index series) and the second scan (= after the ECT index series), as well as the MR scanner and the sequences used.

Site	Time point first scan	Time point second scan	MRI parameters
Aachen	Day before the first ECT treatment	Minimum 2 – maximum 16 days after ECT indes series	3 Tesla Siemens MAGNETOM Tim Trio MRI system T1-weighted MP-RAGE sequence with 1.00-mm isotropic resolution (image matrix = 256 × 256 × 176, repetition time 1900 ms, echo time = 2.52 ms, flip angle = 9°)
Heidelberg	5 days prior to ECT	6–8 days after ECT index series	3 Tesla Siemens MAGNETOM Tim Trio MRI system T1-weighted MP-RAGE sequence with isotropic spatial resolution of 1.00-mm isotropic resolution (image matrix = 256 × 256 × 192, repetition time = 1570 ms, echo time = 2.74 ms, flip angle = 15°)
Mannheim	1–2 days prior to ECT	2–7 days after ECT	3 Tesla Siemens MAGNETOM Tim Trio MRI system T1-weighted MPRAGE with 1.00-mm isotropic resolution (image matrix = 256×256×192, repetition time 1570 ms, echo time = 2.75 ms, flip angle = 15°)
Marburg	Within 1 week prior to ECT	Within 1 week after ECT index series	3 Tesla Siemens MAGNETOM Tim Trio MRI system T1-weighted MPRAGE with 1.00-mm isotropic resolution (image matrix = 256 × 256 × 256, repetition time = 1900 ms, echo time = 2.26 ms, flip angle = 9°)
Münster			Gyroscan Intera 3T (Philips Medical Systems, Best, NL) T1-weighted 3D fast gradient echo sequence ('Turbo Field Echo', TFE) with 0.5-mm isotropic resolution (image matrix = 256 × 204 × 160, repetition time = 7.4 ms, echo time = 3.4 ms, flip angle = 9°)

Table 3
The treatment parameters at the five sites. Reported are the methods for determining the first stimulus dose (age method vs. titration method), the initial electrode placement and the adjustment of stimulus dose and electrode position in the course of the treatment. RUL = right unilateral electrode position, LART = left anterior-right temporal electrode position, BL = bilateral electrode position.

Site	Initial dose finding	Initial electrode placement	Adjustment in the course of treatment	pulse width (ms)	Anesthesia
Aachen	Age method	RUL	Switch to LART, if a sufficient general seizure could not be elicited even after increasing the electric charge or if no clinical response was observed.		
Heidelberg	Titration method	RUL	Further adjustments to stimulus intensity were made as necessary for inadequate seizure duration, defined as < 25 s of electroencephalogram seizure activity		Etomidate followed by succinylcholine.
Mannheim	Titration method	RUL/BL	According to seizure quality and clinical outcome		Thiopental or S-ketamine and succinylcholine for muscle relaxation.
Marburg	Titration method	RUL	Switch to BL in case of insufficient response	0.5	S-ketamine and succinylcholine for muscle relaxation.
Münster	Age method	RUL	Switch to BL in case of insufficient response	0.5	

determined by identifying the most likely behavioral domains, given activation in a particular region/set of regions. This likelihood P (Task|Activation) can be derived from P(Activation|Task) as well as P (Task) and P(Activation) using Bayes' rule. Significance (at $p < 0.05$, corrected for multiple comparisons using FDR) was then assessed by means of a chi-squared test.

2.4. Multi-modal connectivity analyses

Task-independent and task-dependent functional connectivity analyses were used to investigate the functional connectivity across brain states of the regions that emerged from the cross-sectional analyses. The regions that emerged from each of the contrasts were used as regions of interest.

2.4.1. Task-independent – resting-state functional connectivity

Seed-based RS analysis was used to investigate the task-independent functional connectivity of each of the regions that emerged from the VBM analysis. Resting-state fMRI images of 192 healthy volunteers were obtained from the Enhanced Nathan Kline Institute – Rockland Sample (Nooner et al., 2012). The local ethics committee of the Heinrich-Heine University in Düsseldorf approved re-analysis of the data. During RS acquisition, subjects were asked to look at a fixation cross, not think about anything in particular and not to fall asleep. The image acquisition was performed on a Siemens TimTrio 3T scanner using BOLD contrast [gradient-echo EPI pulse sequence, TR = 1.4 s, TE = 30 ms, flip angle = 65°, voxel size = 2.0 mm × 2.0 mm × 2.0 mm, 64 slices, 404 volumes]. Physiological and movement artifacts were removed from the RS data by using FIX (FMRIB's ICA-based Xnoiseifier, version 1.061 as implemented in FSL 5.0. (Salimi-Khorshidi et al., 2014; Griffanti et al., 2014). This step decomposes the data into independent components (ICs) and identifies noise components using a large number of distinct spatial and temporal features via pattern classification. Unique variance related to the identified artefactual ICs is then regressed from the data together with 24 movement parameters (including derivatives and 2nd order effects as previously described and evaluated; cf. Satterthwaite et al., 2013). Data were further preprocessed using SPM8 (Wellcome Trust Centre for Neuroimaging, London) and in-house Matlab scripts. The first four scans were excluded prior to further analyses, the remaining EPI images corrected for head movement using a two-pass (alignment to the initial volume followed by alignment to the mean after the first pass) affine registration. The mean EPI image for each subject was then spatially normalized to the ICBM-152 reference space using the "unified segmentation" approach (Ashburner and Friston, 2005). The resulting deformation was applied to the individual EPI volumes, which were subsequently smoothed with a 5-mm FWHM Gaussian kernel to improve the signal-to-noise ratio and to compensate for residual anatomic variations. The time-course of each seed was extracted per subject by computing the first eigenvariate of the time-series of all voxel within 5 mm of the seed coordinate. To reduce spurious correlations, variance explained by the mean white matter and cerebral spinal fluid signal were removed from the time series, which was subsequently band-pass filtered preserving frequencies between 0.01 and 0.08 Hz. The processed time-course of each seed was then correlated with the (identically processed) time-series of all other gray-matter voxels in the brain using linear (Pearson) correlation. The resulting correlation coefficients were transformed into Fisher's z-scores, which were entered in a second-level ANOVA for group analysis including age and gender as covariates of no interest. The data was then subjected to non-parametric permutation based inference and thresholded at $p < 0.05$ corrected for multiple comparisons using FWE on the cluster level.

2.4.2. Task-dependent: meta-analytical connectivity modeling (MACM)

Meta-analytical connectivity modeling (MACM) was used to

characterize the whole-brain connectivity of each seed region during the execution of experimental tasks through the identification of significant co-activations with the seed across many individual experiments (Eickhoff et al., 2009; Laird et al., 2013). It thus benefits from the fact that a large number of such studies are now available in a highly standardized format through the BrainMap database (Laird et al., 2011; Fox and Hendler, 2014). First, all experiments that feature at least one focus of activation in a particular seed region were identified in BrainMap. Next, the retrieved experiments were subjected to a quantitative meta-analysis using the revised activation likelihood estimation (ALE) algorithm (Eickhoff et al., 2009, 2012; Turkeltaub et al., 2012). This algorithm treats the activation foci reported in the experiments as spatial probability distributions rather than single points, and aims at identifying brain areas that show convergence of activation across experiments. Importantly, convergence was assessed across all the activation foci reported in these experiments. Consequently, any significant convergence outside the seed indicates consistent co-activation and hence functional connectivity. Statistical significance was assessed at $p < 0.05$ after correction for multiple comparisons (Eickhoff et al., 2016).

2.4.3. Consensus connectivity networks

A minimum statistic conjunction between the task-dependent and task-independent functional connectivity maps was performed to generate a consensus connectivity network representing the functional connectivity across brain states for each of the regions that emerged from the VBM analysis. The regions present in the resulting consensus connectivity networks were functionally characterized using the method explained above.

3. Results

3.1. VBM analysis

The VBM analysis resulted in no significant differences for the pre-ECT-Pat > post-ECT-Pat contrast (Fig. 1A). Conversely, significant widespread GMV increase was found for the post-ECT-Pat > pre-ECT-Pat contrast in the bilateral insular cortices, left precentral gyrus, left putamen, right postcentral gyrus, right middle frontal gyrus, right superior frontal gyrus and right caudate. A region in the left fusiform gyrus extending into the middle temporal gyrus was found to have higher GMV for the Con > pre-ECT-Pat contrast (Fig. 1C). No significant differences were yielded when comparing the pre-ECT-Pat > Con contrast (Fig. 1D). A similar region, albeit smaller and more restricted to the fusiform gyrus was still found to have higher GMV in controls when compared with patients after treatment (Fig. 1E). The post-ECT-Pat > Con contrast yielded significant right-hemispheric GMV increase in areas of the hippocampus and amygdala extending into the thalamus (Fig. 1F, Table 4).

When carrying out functional characterization using BrainMap, the wide-spread area that was found to have a significant GMV increase for the post-ECT-Pat > pre-ECT-Pat contrast was found to be associated with emotion, perception and action execution (Fig. 1B). The region in the left fusiform gyrus extending into the middle temporal gyrus (Fig. 1C) that was found to have higher GMV for the Con > pre-ECT-Pat contrast was functionally associated with language, perception, action observation and interoception, while the region that was found significant for the Con > post-ECT-Pat contrast was found to be functionally associated with language, action observation and action execution. Finally, the region yielded from the post-ECT-Pat > Con contrast was

Table 4
Coordinates of the peak maxima and the size for each of the clusters that stem from our longitudinal intra-individual contrasts (above) and the cross-sectional comparisons (below).

	Peak coordinates			Cluster size
	x	*y*	*z*	
Longitudinal intra-individual contrasts (paired t-test)				
pre-ECT-Pat > post-ECT-Pat	*No significant differences*			
post-ECT-Pat > pre-ECT-Pat	38	0	16	23,868
	−1	−29	52	6999
	−37	−8	18	3479
	46	−34	55	2226
	14	4	23	1367
	−34	−25	−7	1150
	36	9	36	944
	22	−6	75	728
Cross-sectional contrasts (two-sample t-tests)				
con > pre-ECT-Pat	−48	−64	−20	2797
pre-ECT-Pat > con	*No significant differences*			
con > post-ECT-Pat	−46	−62	−18	764
post-ECT-Pat > con	22	−9	−7	1065

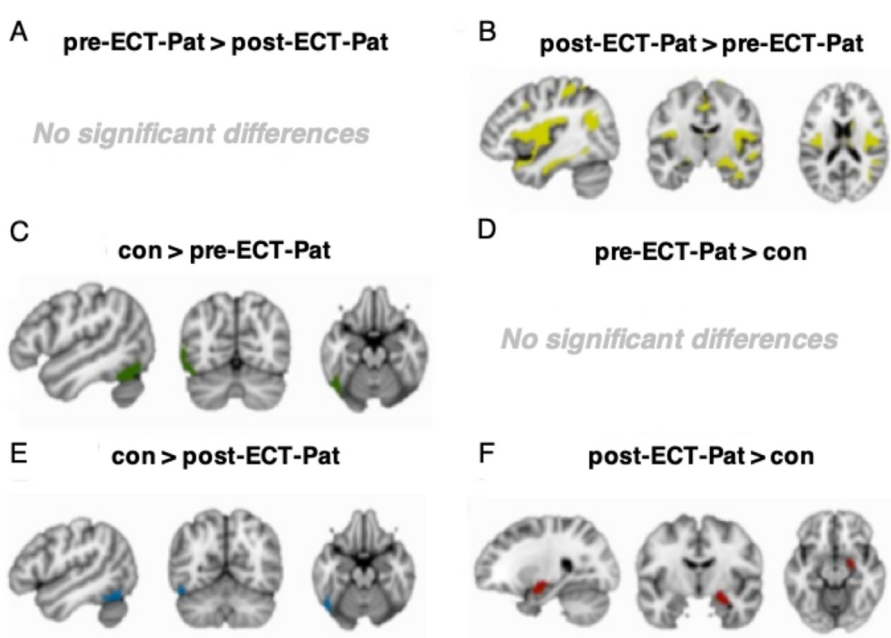

Fig. 1. VBM results in (A) patients before treatment when compared to patients after treatment, (B) patients after treatment when compared to patients before treatment, (C) healthy controls when compared to patients before treatment, (D) patients before treatment when compared to healthy controls, (E) healthy controls when compared to patients after treatment and, (F) patients after treatment when compared to healthy controls. All results were assessed for statistical significance at a conservative threshold of $p < 0.001$, FWE-corrected for multiple comparisons, $k > 500$.

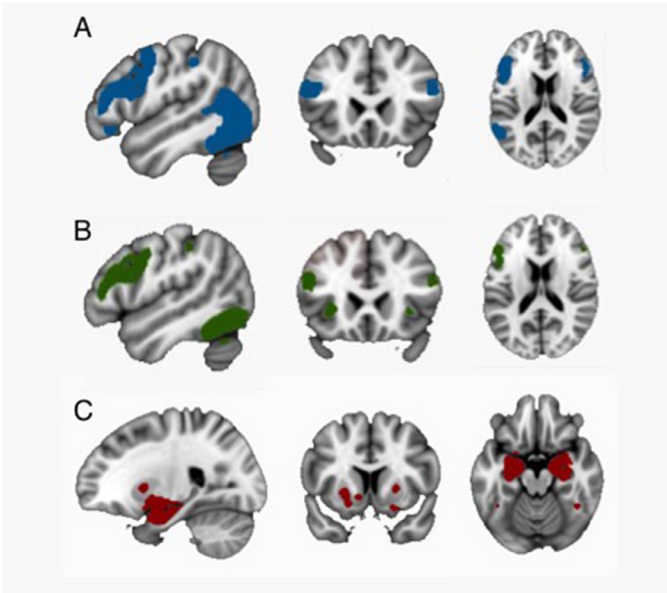

Fig. 2. Functional connectivity maps across brain states of regions emerging from (A) Con > pre-ECT-Pat, (B) Con > post-ECT-Pat and, (C) post-ECT-Pat > Con contrast. All results were assessed at $p < 0.05$, FEW-corrected for multiple comparisons, $k > 10$.

found to be associated with emotion processing, perception, cognition and interoception.

3.2. Consensus connectivity maps

Consensus connectivity maps were calculated for the regions that resulted from the VBM analyses of the Con > pre-ECT-Pat, Con > post-ECT-Pat, and the post-ECT-Pat > Con contrasts. Given its large size, it did not appear as meaningful to compute consensus connectivity maps for the contrast pre-ECT-Pat < post-ECT-Pat. These consensus connectivity maps represent the functional connectivity of the original emerging cluster across brain states.

The consensus connectivity map of the cluster that emerged from the Con > pre-ECT-Pat contrast showed interactions with bilateral regions in the middle temporal gyrus, fusiform gyrus, inferior frontal gyrus, intraparietal sulcus and superior parietal lobe (Fig. 2A). These regions were collectively found to be associated with language, perception, spatial cognition, reasoning, working memory, attention and action observation.

Similarly, the cluster in the fusiform gyrus that emerged from the Con > post-ECT-Pat contrast showed interactions with bilateral regions in the fusiform gyrus, inferior frontal gyrus intraparietal sulcus and superior parietal lobe (Fig. 2B). Additional interactions with the bilateral insula and left precentral gyrus were also noted. The resulting regions were found to be functionally associated with language, perception, spatial cognition, working memory, attention and action observation.

The consensus connectivity map of the cluster that emerged from the post-ECT-Pat > Con contrast showed interactions with regions in the bilateral fusiform gyrus, putamen (Fig. 2C). These regions were found to be mainly functionally associated with emotion, perception, memory and interoception.

4. Discussion

4.1. Grey matter changes in the course of ECT and their potential relationship to the main effect of the treatment

At least in industrialized countries, therapy-resistant depression is usually the major domain of ECT (Scarano et al., 2000; Leiknes et al., 2012). Increased severity of depressive symptoms at the start of the treatment goes along with a better response to the treatment (Kho et al., 2007). However, it should be noted that ECT is efficacious in ameliorating affective symptoms across the boundaries of different disorders, namely manic episodes (Mukherjee et al., 1994), schizoaffective disorder (Ries et al., 1981) and organic affective disorders, respectively agitation in dementia (Grant and Mohan, 2001; Aksay et al., 2014). Of note, pronounced affective symptoms are also a positive predictor of response to ECT in schizophrenia (Chanpattana et al., 1999; Chanpattana and Chakrabhand, 2001). In contrast, effects of electroconvulsive therapy appear to be less pronounced in schizophrenia patients regarding non-affective symptoms, such as auditory hallucinations (Sommer et al., 2012) or negative symptoms (Chanpattana and Andrade, 2006; Chanpattana and Sackheim, 2010). The findings of our study suggest that these therapeutic effects are mediated via a grey matter increase in the right medial temporal lobe. The affected regions – mainly the right hippocampus and amygdala – are involved in an emotion processing network mainly consisting of classical limbic regions in the bilateral fusiform gyrus and the putamen. The potential of ECT to modulate a central hub in this network provides a potential explanation for the predominant effects on affective symptoms across disorders.

Our longitudinal findings revealed a GMV increase in the bilateral insula. The insula has been previously reported to be an important structure in the pathophysiology of MDD (Nagai et al., 2007; Takahashi et al., 2010; Sprengelmeyer et al., 2011) . Additionally, the insula has been shown to be involved in emotional and sensorimotor monitor processing (Gasquoine, 2014), has extensive connections with default mode network regions and is important in the monitoring of internal states (Damasio et al., 2000). Thus, although still exploratory in nature, it could be speculated that the GMV increase in the insula could be a marker for treatment effects of ECT (Eijndhoven et al., 2016).

Remarkably, some regions involved in the consensus connectivity network also showed an association with mnestic functions. It deserves to be emphasized that cognitive-mnestic impairments affect up to 40 per cent of patients undergoing ECT and are the clinically most relevant side effects of the treatment (Coleman et al., 1996; Rehor et al., 2009; Semkovska and McLoughlin, 2010). Although antero- and retrograde amnestic gaps due to ECT usually remit fully within weeks after the end of the treatment, these side effects are the most frequent reason for patients to discontinue the treatment (Eschweiler et al., 2007). Hippocampal dysfunction has been frequently implicated in these memory impairments (Van Oostroom et al., 2018). As shown by our study, ECT led to grey matter increases in a cluster that encomprised not only the right amygdala, but also parts of the hippocampus. Our finding of network properties not only related to emotion, but also to mnestic functions, indicate that the main effect and the side effects of the treatment might be mediated by circuits that are – at least in certain hubs – spatially in close proximity to each other. Future aims to improve the ratio between main and side effects will have to consider this close neuroanatomical relationship between these circuits.

A frequently discussed question in the context of ECT-induced brain plasticity is the question, whether the often reported grey matter increases in patients after the index series are a simple restoration of a previous disease-associated atrophy to a healthy state or whether these findings represent more complex healing processes (Lyden et al., 2014). Our data suggests the latter interpretation of these grey matter increases. Patients with major depression at baseline indeed showed a cluster indicating grey matter decreases compared to healthy controls in the left fusiform gyrus. While this finding might appear as rather unrelated to depression at first sight, modeling of the consensus connectivity network of this cluster revealed connectivity with the DLPFC, resulting in a functional association with reasoning, working memory and attention (Zaninotto et al., 2015). These functions, in turn, are

often impaired in major depression. However, grey matter still appeared as decreased after the index series.

Although data from structural MRI alone is definitely not sufficient to draw valid conclusions on the underlying neurobiology of the changes observed in grey matter volumes, we would like to seize the chance to discuss two mechanisms potentially contributing to these changes: changes in neuroplasticity and altered cellular volumes due to dysregulated neuronal ion intake during seizures. Neurotrophic changes have been consistently implicated as a key mediator of antidepressant response, in general, (Santarelli et al., 2003) and in ECT, in specific (Bumb et al., 2015). Consequently, it would be proximate to suspect that a (hyper-)plastic process might be the reason for these structural changes. However, one striking finding reported consistently across neuroimaging studies in ECT patients was a lack of correlation between volume increases in the medial temporal lobe and therapeutic response (Oltedal et al., 2018; Sartorius et al., 2019). Consequently, we would regard increased neuroplasticity as sole or even main cause for these changes as unlikely. Given that neuroplastic processes are widely regarded as necessary for an antidepressant response (Santarelli et al., 2003), those should, - if indeed detectable by structural MRI - therefore, be correlated with treatment effects. Despite these considerations, we certainly cannot exclude the possibility that these volume increases are also caused by increased neuroplasticity. Another potential explanation for these volume increases could be dysregulated neuronal ion intake during seizures that leads to a subsequent increase of neuronal cellular volumes. However, although such a mechanism has been shown to occur in epileptogenic seizures (Glykys et al., 2017s), it has not been researched in ECT to our knowledge. Future imaging studies focusing in particular on changes of extra- and intracellular sodium levels could provide important new insights into this question.

Identifying common mechanisms of different antidepressant treatment strategies is a major avenue towards understanding the underlying (patho-)physiological processes and could help to optimize treatments. TMS, besides ECT, is one of the most frequently applied brain stimulation techniques. Unfortunately, most of the literature on TMS reports findings of functional MRI studies (Philip et al., 2018). However a recent structural MRI study on patients with major depression undergoing a high-frequency left prefrontal TMS stimulation reported a hippocampal volume increase that was lateralized to the left side. The amygdala was not shown to be structurally altered (Hayasaka et al., 2017). While these results should be certainly reproduced in independent samples, they might indicate that structures of the medial temporal lobe might mediate the therapeutic response of ECT, but that the two treatments might differ with regard to lateralization and their effects on the amygdala.

4.2. Right-lateralization of hippocampal volume increase

One finding of our study is a hippocampal volume increase lateralized to the right hemisphere. This finding is corroborated by another recent pooled multicenter study which also reports a lateralization of volume increases to the right hippocampus (Oltedal et al., 2018). Another meta-analysis revealed no overall difference, but still a numerical difference with larger volume increases of the right hippocampus (Wilkinson et al., 2017). A recent study using data overlapping with our sample has reported a sub-analysis on patients that had only received RUL ECT, and found that this subgroup did not significantly differ from the rest of the group with regards to GMV increases. This seems to indicate that electrode position alone might not be the only reason for the laterality of GM increases. The explanation of the lateralization to the right hemisphere that is reported in the present study remains largely unclear, however, we would suggest that this could be additionally been influenced by the underlying disease itself, since functional brain abnormalities in the right hemisphere have been frequently reported in mood and stress related disorders (Cole et al., 2011; Dunham et al., 2009).

4.3. Hippocampal changes and their potential effects on mnestic side effects of ECT

Volume changes of the hippocampus during the course of ECT have been repeatedly reported by MRI studies (Nordanskog et al., 2010, 2014; Tendolkar et al., 2013; Abbott et al., 2014). These findings were usually interpreted as gross morphological correlates of neurotrophic effects, such as increased neurogenesis, enhanced synaptogenesis or heightened axonal tropism (Kondryatev et al., 2002; Santarelli et al., 2003; Piccinni et al., 2009; Tang et al., 2012; Inta et al., 2013), and, thus, associated with therapeutic response. Consequently, the assumption of a positive correlation between hippocampal volume increase and treatment response has been the prevalent notion in the field (Tendolkar et al., 2013; Dukart et al., 2014; Wilkinson et al., 2017). Recent data has challenged this hypothesis: hippocampal volume was shown to be correlated with the number of treatments, but not with antidepressant treatment response in a large multi-site sample of patients with major depression (Oltedal et al., 2018). The authors interpreted these findings as evidence that hippocampal volume increases might be an epiphenomenon that is unrelated to the antidepressant mechanism of ECT. This idea has been previously discussed also by other authors (Nickl-Jockschat et al., 2016). Moreover, a recent study using a sample overlapping with the present study, has shown that changes in the HAMD scores do not predict changes in gray matter volume (Sartorius et al., 2019). Specifically, changes in grey matter volumes did not correlate with clinical improvement as measured by the HAMD.

The findings of our study seem to provide a possible explanation for these seemingly contradicting results between the findings reported by Oltedal and colleagues and Sartorius and colleagues as compared with previous studies (Tendolkar et al., 2013; Dukart et al., 2014; Wilkinson et al., 2017). Our results indicate that ECT causes structural changes in a region that contains hubs for two important networks: one associated with emotion-processing and one related to memory. As hippocampal regions are known to play a pivotal role in memory, but a less prominent one in the processing of emotions, the interpretation of hippocampal volume increases due to ECT could indeed be an epiphenomenon (Oltedal et al., 2018), whereas structural changes in the amygdala could be responsible for mediating the antidepressant effect. This is supported by a recent study showing that ECT leads to a normalization of amygdala reactivity to emotional stimuli, and further, that the extent of changes in amygdala reactivity is associated with symptom improvement (Redlich et al., 2017). Therefore, given the results of our study presented here, we would interpret the negative results reported by previous studies as an indicator that the location of the grey matter increases, and their subsequent influence on neural circuits were more important than their extent.

Of note, while our data certainly does not allow to infer on changes of connectivity in patients with MDD due to ECT, the results of our study seem to support the idea that changing functional connectivity is a main therapeutic mechanism of electroconvulsive therapy (Perrin et al., 2012). Following this line of thought, it is tempting to speculate that volume changes of the amygdala might not be linearly correlated with therapeutic response. Changes of network connectivity might be more important than volume increases per se.

4.4. Methodological considerations

We here report data from a retrospective multi-site study. This study design goes along with various limitations. For example, there were no a priori protocols for electrode placement, adjustment of charge due to seizure quality, standardized end points or scanner parameters. While we have adjusted for potential site effects as confounds, it should be noted that prospective multi-site studies do not go along with these limitations. However, as ECT patients are a comparatively rare clientele, at least in industrialized countries (Case et al., 2013; Loh et al.,

2013) and often remain reluctant to participate in neuroimaging studies, our pooling approach appears as worthwhile to gain further insight into the therapeutic mechanisms of ECT.

To delineate the physiological task-dependent and task-independent networks of structurally altered brain regions, we here used two well-validated and widely used approaches (Laird et al., 2009, 2013). While these approaches allow robust inference on co-activation patterns in healthy subjects, it should be noted that these results do not allow direct inference on changes of connectivity in patients undergoing ECT. However, we would like to point out that the use of these approaches was motivated by our main aim to better understand the *physiological* properties of brain regions that are affected by ECT treatment since the characterization of the *physiological* properties of a brain region is a prerequisite to fully understand its role in disease- and treatment-related processes. Therefore, our findings here can serve to generate hypotheses for future neuroimaging studies on the therapeutic mechanisms of ECT.

We here enrolled patients with major depressive disorder. This certainly helps to create a homogeneous patient sample, but certainly limits the generalization of our findings. Future studies on patient cohorts with different disorders undergoing ECT will elucidate, whether electroconvulsive therapy exerts similar structural changes across disorders.

It remains open, how this emotion processing network is related to the functional neuroanatomy of depression. A major obstacle in this regard seems to be the clinical and pathophysiological heterogeneity of depression. Previous meta-analyses on fMRI studies of disturbed neural networks have repeatedly reported changes in fronto-limbic networks (cf. DeRubeis et al., 2008), but often differ markedly with regard to the exact brain regions that are affected (Fitzgerald et al., 2008; Diener et al., 2012; Graham et al., 2013; Lai, 2014; Palmer et al., 2015). The currently largest meta-analysis did not find any convergent results for changes in neural activations associated with cognitive of affective tasks in MDD patients (Müller et al., 2017). Future studies will help to elucidate, whether – and if yes: how – this pathophysiological heterogeneity corresponds to treatment response. An additional point to consider is the fact that depression is well known to be comorbid with anxiety disorders, with epidemiological studies showing consistently high comorbidity rates ranging from 40% to 80% (Hirschfeld, 2001; Lamers et al., 2011). Since a significant number of patients with such a comorbidity have been found to be treatment-resistant (Breier et al., 1984; Clark and Watson, 1991; Gorman, 1996), the possibility of comorbidity with anxiety in the sample used for the current study should not be excluded. As the insula appears as a major cerebral hub mediating anxiety symptoms via various neural mechanisms, our finding of longitudinal grey matter increases in the right insula could be indicative of an effect of ECT especially on symptoms related to anxiety. Due to the retrospective nature of our study, it was, unfortunately, not possible to follow up further on whether the clinical effects of ECT in our cohort were driven by an improvement mainly of depressive core symptoms (depressive mood, lack of energy, anhedonia), anxiety-related depressive symptoms or comorbid anxiety disorders. The therapeutic effects and, hence, the underlying mechanisms, of ECT are usually seen as rather unspecific. Consequently, our findings of grey matter changes in the insula that might cause a general effect on anxiety levels fit very well into that hypothesis.

Inferences from MRI data sets on a microstructural level certainly remain speculative. Consequently, our data cannot provide answers to the question, whether the observed grey matter increases are indeed caused by neurotrophic effects or not. However, it deserves to be pointed out that little has been known so far about how these structural effects are related to functional brain networks. Our study addresses this open question and provides first data-driven evidence that ECT induces grey matter increases in a hub of an emotion processing network.

5. Conclusion

We here provide evidence for grey matter increases mediated by ECT in a region of the medial temporal lobe, an important hub for networks related to emotion and cognition. This appears as a plausible antidepressant mechanism and could explain the efficacy of ECT not only in the treatment of unipolar depression, but also of affective symptoms across heterogeneous disorders.

Declaration of Competing Interest

The authors state that they have no conflict of interest.

References

Abbott, C.C., Jones, T., Lemke, N.T., Gallegos, P., McClintock, S.M., Mayer, A.R., et al., 2014. Hippocampal structural and functional changes associated with electroconvulsive therapy response. Transl. Psychiatry 4, e483.

Aksay, S.S., Hausner, L., Frölich, L., Sartorius, A., 2014. Objective cognitive performance associated with electroconvulsive therapy for depression: a systematic review and meta-analysis. Neuropsychiatr. Dis. Treat. 10, 2147–2151.

American Psychiatric Association, 2001. The Practice of Electroconvulsive Therapy. Recommendations for Treatment, Training, and Privileging. Washington DCauthor.

Ashburner, J., Friston, K.J., 2005. Unified segmentation. Neuroimage 26 (3), 839–851.

Ashburner, J., Friston, K.J., 2011. Diffeomorphic registration using geodesic shooting and Gauss–Newton optimisation. Neuroimage 55 (3), 954–967.

Bouckaert, F., Dols, A., Emsell, L., De Winter, F.L., Vansteelandt, K., Claes, L., et al., 2016. Relationship between hippocampal volume, serum BDNF, and depression severity following electroconvulsive therapy in late-life depression. Neuropsychopharmacology 41 (11), 2741–2748.

Breier, A., Charney, D.S., Heninger, G.R., 1984. Major depression in patients with agoraphobia and panic disorder. Arch. Gen. Psychiatry 41 (12), 1129–1135.

Bumb, J.M., Aksay, S.S., Janke, C., Kranaster, L., Geisel, O., Gass, P., et al., 2015. Focus on ECT seizure quality: serum BDNF asa peripheral biomarker in depressed patients. Eur. Arch. Psychiatry Clin. Neurosci. 265 (3), 227–232.

Case, B.G., Bertollo, D.N., Laska, E.M., Price, L.H., Siegel, C.E., Olfson, M., Marcus, S.C., 2013. Declining use of electroconvulsive therapy in United States general hospitals. Biol. Psychiatry 73 (2), 119–126.

Cerletti, U., Bini, L., 1938. l'Elletroshock. Riv. Sper. Freniatr. Med. Leg. Alein. Ment. 19, 266–268.

Chanpattana, W., Chakrabhand, M.L., Kongsakon, R., Techakasem, P., Buppanharun, W., 1999. Short-term effect of combined ECT and neuroleptic therapy in treatment-resistant schizophrenia. J. ECT 15 (2), 129–139.

Chanpattana, W., Chakrabhand, M.L., 2001. Combined ECT and neuroleptic therapy in treatment-refractory schizophrenia: prediction of outcome. Psychiatry Res. 105 (1–2), 107–115.

Chanpattana, W., Andrade, C., 2006. ECT for treatment-resistant schizophrenia: a response from the far East to the UK. Nice report. J. ECT 22 (1), 4–12.

Chanpattana, W., Sackeim, H.A., 2010. Electroconvulsive therapy in treatment-resistant schizophrenia: prediction of response and the nature of symptomatic improvement. J. ECT 26 (4), 289–298.

Chen, F., Madsen, T.M., Wegener, G., Nyengaard, J.R., 2009. Repeated electroconvulsive seizures increase the total number of synapses in adult male rathippocampus. Eur. Neuropsychopharmacol. 19 (5), 329–338.

Clark, L.A., Watson, D., 1991. Tripartite model of anxiety and depression: psychometric evidence and taxonomic implications. J. Abnorm. Psychol. 100 (3), 316.

Cole, J., Costafreda, S.G., McGuffin, P., Fu, C.H., 2011. Hippocampal atrophy in first episode depression: a meta-analysis of magnetic resonance imaging studies. J. Affect. Disord. 134 (1–3), 483–487.

Coleman, E.A., Sackeim, H.A., Prudic, J., Devanand, D.P., McElhiney, M.C., Moody, B.J., 1996. Subjective memory complaints prior to and following electroconvulsive therapy. Biol. Psychiatry 39 (5), 346–356.

Damasio, A.R., Grabowski, T.J., Bechara, A., Damasio, H., Ponto, L.L., Parvizi, J., Hichwa, R.D., 2000. Subcortical and cortical brain activity during the feeling of self-generated emotions. Nat. Neurosci. 3 (10), 1049.

DeRubeis, R.J., Siegle, G.J., Hollon, S.D., 2008. Cognitive therapy versus medication for depression: treatment outcomes and neural mechanisms. Nat. Rev. Neurosci. 9 (10), 788–796.

Diener, C., Kuehner, C., Brusniak, W., Ubl, B., Wessa, M., Flor, H., 2012. A meta-analysis of neurofunctional imaging studies of emotion and cognition in major depression. Neuroimage 61 (3), 677–685.

Dukart, J., Regen, F., Kherif, F., Colla, M., Bajbouj, M., Heuser, I., et al., 2014. Electroconvulsive therapy-induced brain plasticity determines therapeutic outcome in mood disorders. Proc. Natl. Acad. Sci. USA 111 (3), 1156–1161.

Dunham, J.S., Deakin, J.F.W., Miyajima, F., Payton, A., Toro, C.T., 2009. Expression of hippocampal brain-derived neurotrophic factor and its receptors in Stanley consortium brains. J. Psychiatr. Res. 43 (14), 1175–1184.

Eickhoff, S.B., Laird, A.R., Grefkes, C., Wang, L.E., Zilles, K., Fox, P.T., 2009. Coordinate-based activation likelihood estimation meta-analysis of neuroimaging data: a random-effects approach based on empirical estimates of spatial uncertainty. Hum. Brain Mapp. 30 (9), 2907–2926.

Eickhoff, S.B., Bzdok, D., Laird, A.R., Kurth, F., Fox, P.T., 2012. Activation likelihood estimation meta-analysis revisited. Neuroimage 59 (3), 2349–2361.
Eickhoff, S.B., Nichols, T.E., Laird, A.R., Hoffstaedter, F., Amunts, K., Fox, P.T., et al., 2016. Behavior, sensitivity, and power of activation likelihood estimation characterized by massive empirical simulation. Neuroimage 137, 70–85.
Van Eijndhoven, P., Mulders, P., Kwekkeboom, L., Van Oostrom, I., van Beek, M.H.C.T., Janzing, J., ... Tendolkar, I., 2016. Bilateral ECT induces bilateral increases in regional cortical thickness. Translational psychiatry 6 (8), e874.
Eschweiler, G.W., Vonthein, R., Bode, R., Huell, M., Conca, A., Peters, O., et al., 2007. Clinical efficacy and cognitive side effects of bifrontal versus right unilateral electroconvulsive therapy (ECT): a short-term randomised controlled trial in pharmacoresistant major depression. J. Affect. Disord. 101 (1–3), 149–157.
Fitzgerald, P.B., Laird, A.R., Maller, J., Daskalakis, Z.J., 2008. A meta-analytic study of changes in brain activation in depression. Hum. Brain Mapp. 29 (6), 683–695.
Fox, P.T., Lancaster, J.L., 2002. Opinion: mapping context and content: the BrainMap model. Nat. Rev. Neurosci. 3 (4), 319–321.
Fox, P., Hendler, J., 2014. The science of data science. Big Data 2 (2), 68–70.
Gasquoine, P.G., 2014. Contributions of the insula to cognition and emotion. Neuropsychol. Rev. 24 (2), 77–87.
Glykys, J., Dzhala, V., Egawa, K., Kahle, K.T., Delpire, E., Staley, K., 2017. Chloride dysregulation, seizures, and cerebral edema: a relationship with therapeutic potential. Trends Neurosci. 40 (5), 276–294.
Goodkind, M., et al., 2015. Identification of a common neurobiological substrate for mental illness. JAMA Psychiatry 72(4): (305–15).
Gorman, J.M., 1996. Comorbid depression and anxiety spectrum disorders. Depress. Anxiety 4 (4), 160–168.
Graham, J., Salimi-Khorshidi, G., Hagan, C., Walsh, N., Goodyer, I., Lennox, B., Suckling, J., 2013. Meta-analytic evidence for neuroimaging models of depression: state or trait. J. Affect. Disord. 151 (2), 423–431.
Grant, J.E., Mohan, S.N., 2001. Treatment of agitation and aggression in four demented patients using ECT. J. ECT 17 (3), 205–209.
Griffanti, L., Salimi-Khorshidi, G., Beckmann, C.F., Auerbach, E.J., Douaud, G., Sexton, C.E., et al., 2014. ICA-based artefact removal and accelerated fMRI acquisition for improved resting state network imaging. Neuroimage 95, 232–247.
Hayasaka, S., Nakamura, M., Noda, Y., Izuno, T., Saeki, T., Iwanari, H., Hirayasu, Y., 2017. Lateralized hippocampal volume increase following high-frequency left prefrontal repetitive transcranial magnetic stimulation in patients with major depression. Psychiatry Clin. Neurosci. 71 (11), 747–758.
Hirschfeld, R.M., 2001. The comorbidity of major depression and anxiety disorders: recognition and management in primary care. Prim. Care Companion J. Clin. Psychiatry 3 (6), 244.
Inta, D., Lima-Ojeda, J.M., Lau, T., Tang, W., Dormann, C., Sprengel, R., et al., 2013. Electroconvulsive therapy induces neurogenesis in frontal rat brain areas. PLoS One 8 (7), e69869.
Kho, K.H., Blansjaar, B.A., Vothknecht, S., Cornelissen, N.M., Koomen, E., Zwinderman, A.H., Linszen, D.H., 2007. A study into predictors for the speed of response to electroconvulsive therapy. J. ECT 20 (3), 154–159.
Kondratyev, A., Ved, R., Gale, K., 2002. The effects of repeated minimal electroconvulsive shock exposure on levels of mRNA encoding fibroblast growth factor-2 and nerve growth factor in limbic regions. Neuroscience 114 (2), 411–416.
Lai, C.H., 2014. Patterns of cortico-limbic activations during visual processing of sad faces in depression patients: a coordinate-based meta-analysis. J. Neuropsychiatry Clin. Neurosci. 26 (1), 34–43.
Laird, A.R., Eickhoff, S.B., Li, K., Robin, D.A., Glahn, D.C., Fox, P.T., 2009. Investigating the functional heterogeneity of the default mode network using coordinate-basedmeta-analytic modeling. J. Neurosci. 29 (46), 14496–14505.
Laird, A.R., Eickhoff, S.B., Fox, P.M., Uecker, A.M., Ray, K.L., Saenz Jr., J.J., et al., 2011. The BrainMap strategy for standardization, sharing, and meta-analysis of neuroimaging data. BMC Res. Notes 4, 349.
Laird, A.R., Eickhoff, S.B., Rottschy, C., Bzdok, D., Ray, K.L., Fox, P.T., 2013. Networks of task co-activations. Neuroimage 80, 505–514.
Lamers, F., van Oppen, P., Comijs, H.C., Smit, J.H., Spinhoven, P., van Balkom, A.J., Nolen, W.A., Zitman, F.G., Beekman, A.T.F., Penninx, B.W.J.H., 2011. Comorbidity patterns of anxiety and depressive disorders in a large cohort study: the Netherlands Study of Depression and Anxiety (NESDA). J. Clin. Psychiatry 72, 341–348.
Leiknes, K.A., Jarosh-von Schweder, L., Høie, B., 2012. Contemporary use and practice of electroconvulsive therapy worldwide. Brain Behav. 2 (3), 283–344.
Loh, N., Nickl-Jockschat, T., Sheldrick, A.J., Grözinger, M., 2013. Accessibility, standards and challenges of electroconvulsive therapy in Western industrialized countries: a German example. World J. Biol. Psychiatry 14 (6), 432–440.
Lyden, H., Espinoza, R.T., Pirnia, T., Clark, K., Joshi, S.H., Leaver, A.M., et al., 2014. Electroconvulsive therapy mediates neuroplasticity of white matter microstructure in major depression. Transl. Psychiatry 4, e380 2014.
Malberg, J.E., Eisch, A.J., Nestler, E.J., Duman, R.S., 2000. Chronic antidepressant treatment increases neurogenesis in adult rat hippocampus. J. Neurosci. 20 (24), 9104–9110.
Minelli, A., Zanardini, R., Abate, M., Bortolomasi, M., Gennarelli, M., Bocchio-Chiavetto, L., 2011. Vascular Endothelial Growth Factor (VEGF) serum concentration during electroconvulsive therapy (ECT) in treatment resistant depressed patients. Prog. Neuropsychopharmacol. Biol. Psychiatry 35 (5), 1322–1325.
Mukherjee, S., Sackeim, H.A., Schnur, D.B., 1994. Electroconvulsive therapy of acute manic episodes: a review of 50 years' experience. Am. J. Psychiatry 151 (2), 169–176.
Müller, V.I., Cieslik, E.C., Serbanescu, I., Laird, A.R., Fox, P.T., Eickhoff, S.B., 2017. Altered brain activity in unipolar depression revisited: meta-analyses of neuroimaging studies. JAMA Psychiatry 74 (1), 47–55.
Nagai, M., Kishi, K., Kato, S., 2007. Insular cortex and neuropsychiatric disorders: a review of recent literature. Eur. Psychiatry 22 (6), 387–394.
Nickl-Jockschat, T., Rottschy, C., Thommes, J., Schneider, F., Laird, A.R., Fox, P.T., Eickhoff, S.B., 2015. Neural networks related to dysfunctional face processing in autism spectrum disorder. Brain Struct. Funct. 220 (4), 2355–2371.
Nickl-Jockschat, T., Palomero Gallagher, N., Kumar, V., Hoffstaedter, F., Brügmann, E., Habel, U., et al., 2016. Are morphological changes necessary to mediate the therapeutic effects of electroconvulsive therapy? Eur. Arch. Psychiatry Clin. Neurosci. 266 (3), 261–267.
Nooner, K.B., Colcombe, S.J., Tobe, R.H., Mennes, M., Benedict, M.M., Moreno, A.L., et al., 2012. The NKI-Rockland sample: a model for accelerating the pace of discovery science in psychiatry. Front. Neurosci. 6, 152.
Nordanskog, P., Dahlstrand, U., Larsson, M.R., Larsson, E.M., Knutsson, L., Johanson, A., 2010. Increase in hippocampal volume after electroconvulsive therapy in patients with depression: a volumetric magnetic resonance imaging study. J. ECT 26 (1), 62–67.
Nordanskog, P., Larsson, M.R., Larsson, E.M., Johanson, A., 2014. Hippocampal volume in relation to clinical and cognitive outcome after electroconvulsive therapy in depression. Acta Psychiatr. Scand. 129 (4), 303–311.
Oltedal, L., Narr, K.L., Abbott, C., Anand, A., Argyelan, M., Bartsch, H., et al., 2018. J. Biol. Psychiatry (18), 31534–31538 pii: S0006-3223.
Palmer, S.M., Crewther, S.G., Carey, L.M., Project Team, S.T.A.R.T., 2015. A meta-analysis of changes in brain activity in clinical depression. Front. Hum. Neurosci. 8, 1045.
Perrin, J.S., Merz, S., Bennett, D.M., Currie, J., Steele, D.J., Reid, I.C., Schwarzbauer, C., 2012. Electroconvulsive therapy reduces frontal cortical connectivity in severe depressive disorder. Proc. Natl. Acad. Sci. USA 109 (140), 5464–5468.
Philip, N.S., Barredo, J., Aiken, E., Carpenter, L.L., 2018. Neuroimaging mechanisms of therapeutic transcranial magnetic stimulation for major depressive disorder. Biol. Psychiatry 3 (3), 211–222.
Piccinni, A., Del Debbio, A., Medda, P., Bianchi, C., Roncaglia, I., Veltri, A., et al., 2009. Plasma brain-derived neurotrophic factor in treatment-resistant depressed patients receiving electroconvulsive therapy. Eur. Neuropsychopharmacol. 19 (5), 349–355.
Poeppl, T., 2019. A view behind the mask of sanity: meta-analysis of aberrant brain activity in psychopaths. Mol Psychiatry 24, 463–470.
Qiu, H., Li, X., Zhao, W., Du, L., Huang, P., Fu, Y., et al., 2016. Electroconvulsive therapy-induced brain structural and functional changes in major depressive disorders: a longitudinal study. Med. Sci. Monit. 22, 4577–4586.
Redlich, R., Bürger, C., Dohm, K., Grotegerd, D., Opel, N., Zaremba, D., et al., 2017. Effects of electroconvulsive therapy on amygdala function in major depression – a longitudinal functional magnetic resonance imaging study. Psychol. Med. 47 (12), 2166–2176.
Rehor, G., Conca, A., Schlotter, W., Vonthein, R., Bork, S., Bode, R., et al., 2009. [Relapse rate within 6 months after successful ECT: a naturalistic prospective peer- and self-assessment analysis]. Neuropsychiatric 23 (3), 157–163.
Ries, R.K., Wilson, L., Bokan, J.A., Chiles, J.A., 1981. ECT in medication resistant schizoaffective disorder. Compr. Psychiatry 22 (2), 167–173.
Salimi-Khorshidi, G., Douaud, G., Beckmann, C.F., Glasser, M.F., Griffanti, L., Smith, S.M., 2014. Automatic denoising of functional MRI data: combining independent component analysis and hierarchical fusion of classifiers. Neuroimage 90, 449–468.
Santarelli, L., Saxe, M., Gross, C., Surget, A., Battaglia, F., Dulawa, S., et al., 2003. Requirement of hippocampal neurogenesis for the behavioral effects of antidepressants. Science 301 (5634), 805–809.
Sartorius, A., Demirakca, T., Böhringer, A., Clemm von Hohenberg, C., Aksay, S.S., Bumb, J.M., et al., 2016. Electroconvulsive therapy increases temporal gray matter volume and cortical thickness. Eur. Neuropsychopharmacol. 26 (3), 506–517.
Sartorius, A., Demirakca, T., Böhringer, A., von Hohenberg, C.C., Aksay, S.S., Bumb, J.M., ... Wolf, R.C., 2019. Electroconvulsive therapy induced gray matter increase is not necessarily correlated with clinical data in depressed patients. Brain stimulation 12 (2), 335–343.
Satterthwaite, T.D., Elliott, M.A., Gerraty, R.T., Ruparel, K., Loughead, J., Calkins, M.E., et al., 2013. An improved framework for confound regression and filtering for control of motion artifact in the preprocessing of resting-state functional connectivity data. Neuroimage 64, 240–256.
Scarano, V.R., Felthous, A.R., Early, T.S., 2000. The state of electroconvulsive therapy in Texas. Part I: reported data on 41,660 ECT treatments in 5971 patients. J. Forensic Sci. 45 (6), 1197–1202.
Semkovska, M., McLoughlin, D.M., 2010. Objective cognitive performance associated with electroconvulsive therapy for depression: a systematic review and meta-analysis. Biol. Psychiatry 68 (6), 568–577.
Sommer, I.E., Slotema, C.W., Daskalakis, Z.J., Derks, E.M., Blom, J.D., van der Gaag, M., 2012. The treatment of hallucinations in schizophrenia spectrum disorders. Schizophr. Bull. 38 (4), 704–714.
Sprengelmeyer, R., Steele, J.D., Mwangi, B., Kumar, P., Christmas, D., Milders, M., Matthews, K., 2011. The insular cortex and the neuroanatomy of major depression. J. Affect. Disord. 133 (1–2), 120–127.
Takahashi, T., Yücel, M., Lorenzetti, V., Tanino, R., Whittle, S., Suzuki, M., ... Allen, N.B., 2010. Volumetric MRI study of the insular cortex in individuals with current and past major depression. Journal of affective disorders 121 (3), 231–238.
Tang, S.W., Helmeste, D., Leonard, B., 2012. Is neurogenesis relevant in depression and in the mechanism of antidepressant drug action? A critical review. World J. Biol. Psychiatry 13 (6), 402–412.
Tendolkar, I., van Beek, M., van Oostrom, I., Mulder, M., Janzing, J., Voshaar, R.O., van Eijndhoven, P., 2013. Electroconvulsive therapy increases hippocampal and amygdala volume in therapy refractory depression: a longitudinal pilot study. Psychiatry Res. 214 (3), 197–203.
Turkeltaub, P.E., Eickhoff, S.B., Laird, A.R., Fox, M., Wiener, M., Fox, P., 2012.

Minimizing within-experiment and within- group effects in Activation Likelihood Estimation meta-analyses. Hum. Brain Mapp. 33 (1), 1–13.
UK ECT Review Group, 2003. Efficacy and safety of electroconvulsive therapy in depressive disorders: a systematic review and meta-analysis. Lancet 361 (9360), 799–808.
Van Oostrom, I., van Eijndhoven, P., Butterbrod, E., van Beek, M.H., Janzing, J., Donders, R., et al., 2018. Decreased cognitive functioning after electroconvulsive therapy is related to increased hippocampal volume: exploring the role of brain plasticity. J. ECT 34 (2), 117–123.
Wensing, T., Cieslik, E.C., Müller, V.I., Hoffstaedter, F., Eickhoff, S.B., Nickl-Jockschat, T., 2017. Neural correlates of formal thought disorder: an activation likelihood estimation meta-analysis. Hum. Brain Mapp. 38 (10), 4946–4965.
Wilkinson, S.T., Sanacora, G., Bloch, M.H., 2017. Hippocampal volume changes following electroconvulsive therapy: a systematic review and meta-analysis. Biol. Psychiatry Cognit. Neurosci. Neuroimaging 2 (4), 327–335.
Yrondi, A., Péran, P., Sauvaget, A., Schmitt, L., Arbus, C., 2018. Structural-functional brain changes in depressed patients during and after electroconvulsive therapy. Acta Neuropsychiatr. 30 (1), 17–28.
Zaninotto, L., Guglielmo, R., Calati, R., Ioime, L., Camardese, G., Janiri, L., et al., 2015. Cognitive markers of psychotic unipolar depression: a meta-analytic study. J. Affect. Disord. 174, 580–588.